Photomedicine and Laser Surgery
Volume 33, Number 11, 2015
© Mary Ann Liebert, Inc.
Pp. 1–7
DOI: 10.1089/pho.2014.3856

Removal of Epulis Fissuratum by Er,Cr:YSGG Laser in Comparison with the Conventional Method

AU1 ▶

Cennet Neslihan Eroglu, DDS, PhD,[1] Serap Keskin Tunc,[1] and Sadi Elasan[2]

Abstract

Objective: The present study aimed to compare clinical outcomes during the recovery period after soft tissue surgery performed by an erbium, chromium:yttrium-scandium-gallium-garnet (Er,Cr:YSGG) laser with those after surgery with the conventional method, in which a scalpel was used. ***Methods:*** A total of 44 epulis fissuratum removal surgeries were performed in 30 healthy volunteers using either an Er,Cr:YSGG laser (laser group) or a scalpel (conventional group), with the same number of lesions in each group. Both groups were controlled postoperatively on days 2, 7, 14, and 30. The visual analog scale (VAS) pain scores of the patients and healing, erythema, and suppuration in the surgical area were recorded with scores between 0 and 3. Total wound surface was measured by a ruler according to the Bates–Jensen Wound Assessment Tool. ***Results:*** The results of the present study demonstrated that there were no significant differences between the conventional group using analgesic and the laser group in terms of the VAS scores ($p = 0.744$) and edema ($p = 0.206$). Evaluation of wound surface revealed healing without any problem as of the 2nd day at a rate of 82% in the laser group and 59% in the conventional group. ***Conclusions:*** In conclusion, Er,Cr:YSGG laser was superior to scalpel regarding clinical outcomes, and led to a difference in the use of analgesic and local anesthetic.

Introduction

EPULIS FISSURATUM, which is one of the most common intraoral configurations seen in soft tissue surgery, is a pseudotumor growth with variable degrees of hypertrophy and hyperplasia caused by chronic irritation resulting from poorly adapted dental prostheses and is located over the soft tissues of the vestibular sulcus. The therapeutic choice is surgical excision with appropriate prosthetic reconstruction.[1,2] Variable surgical excision methods are used by clinicians to remove this soft tissue pathology. In addition to the conventional techniques (scalpel, electrocautery), diverse types of lasers such as the erbium, chromium:yttrium-scandium-gallium-garnet (Er,Cr:YSGG), CO_2, neodymium:yttrium–aluminum–garnet (Nd:YAG), and diode lasers have become alternative instruments in soft tissue surgery.[1,3]

In laser surgery procedures, thermal damage to collateral tissues, albeit minimal, is inevitable regardless of the type of laser used.[4,5] It is asserted that this damage is minimal with the use of Er,Cr:YSGG laser.[6] The working principle of Er,Cr:YSGG laser is that emission of laser by water on the surface of tissues enables a smooth, clear, and gentle ablation with minimal damage to tissues. Thus, wounds that are caused by Er,Cr:YSGG laser heal more rapidly.[7–9]

Compared with using a scalpel, the potential advantages of using a laser include the ease of soft tissue ablation; improved hemostasis; sterilization of the surgical field; less edema mechanical trauma, and intra- and postoperative pain; minimum scarring; enhanced patient satisfaction and motivation, fewer or no sutures; and no requirement for topical anesthesia.[10–14] However, when considering availability, the scalpel appears as the first choice in surgical procedures.

The aim of this study was to compare clinical outcomes in patients with epulis fissuratum treated with either Er,Cr:YSGG laser surgery or conventional surgery.

Materials and Methods

The clinical study was conducted in a group of 30 patients (25 females and 5 males; age range, 32–70 years) with a total of 44 epulis fissuratum lesions caused by wearing dentures. The patients were consecutively enrolled between December 2013 and January 2014. None of the patients had a history of epulis fissuratum or any previous surgery. Subjects with systemic diseases such as diabetes mellitus and cardiologic problems or a history of corticosteroid use within the last 3 months were excluded. The study was approved by the local ethics committee and was performed

[1]Department of Oral and Maxillofacial Surgery, Yuzuncu Yil University Faculty of Dentistry, Van, Turkey.
[2]Department of Biostatistics, Yuzuncu Yil University Faculty of Medicine, Van, Turkey.

PHO-2014-3856-ver9-Eroglu_1P.3d 09/09/15 9:46am Page 2

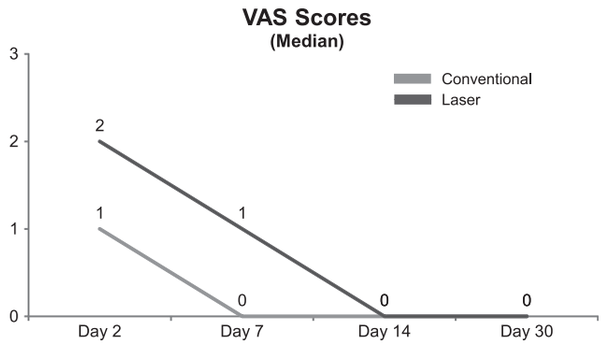

FIG. 1. Mean postoperative visual analog scale (VAS) pain scores in both groups. The VAS scores were assessed on days 2, 7, 14, and 30.

in accordance with the ethical standards laid down in the 1964 Declaration of Helsinki and its later amendments. Informed written consent was obtained from all patients prior to their inclusion in the study.

Patients were randomly assigned to either the conventional group or the laser group. In the conventional group, interventions were performed with the patient under local anesthesia using 4% articaine hydrochloride (HCl) with 1:100,000 epinephrine (80 mg of articaine HCl with 0.020 mg epinephrine; VEM, Ankara, Turkey) in accordance with standard surgery procedures. All surgical procedures were performed by the same surgeon. In the conventional surgery, after exposing the basal part of the lesion vertically, excision was performed such that the borders were in the intact tissue, and the incision was closed primarily after bleeding was controlled. In the laser group, an Er,Cr:YSGG laser (WaterLase iPlus™; USA Biolase® Technology Inc., Irvine, CA) was used with the following modulations (soft tissue-rapid cut-gingival recontouring-H mode): a wavelength of 2780 nm, a pulse duration of 140–200 μs, a repetition frequency of 75 Hz, a power of 2.75 W, and an air/water proportion of 20/40%. The application tip used was the MZ5 (550 μm in diameter, 6 mm in length, and 1 mm in spot size) and it was used with slight contact with target tissue. The power output of this laser with the MZ5 applicator tip can be varied from 0 to 6 W (up to 600 mJ/pulse). Hemostasis was provided with the MZ6 applicator tip (660 μm in diameter, 6 mm in length, 1 mm in spot size) and using the device at

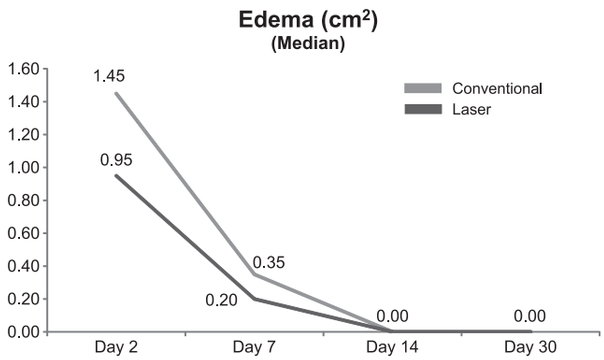

FIG. 2. Mean postoperative edema values in both groups. Edema was assessed on days 2, 7, 14, and 30.

coagulation S-mode with settings of 1.5 W, 50 Hz, water off, and 20% air for bleeding focuses in the region. In the laser group, after fixing the basement of the lesion, the pedicled side was retracted superiorly using a clamp, and the lesion was removed such that the wound borders were in the intact tissue. In the laser group, the wounds occurred after the excisions were allowed for secondary healing. Postoperatively,

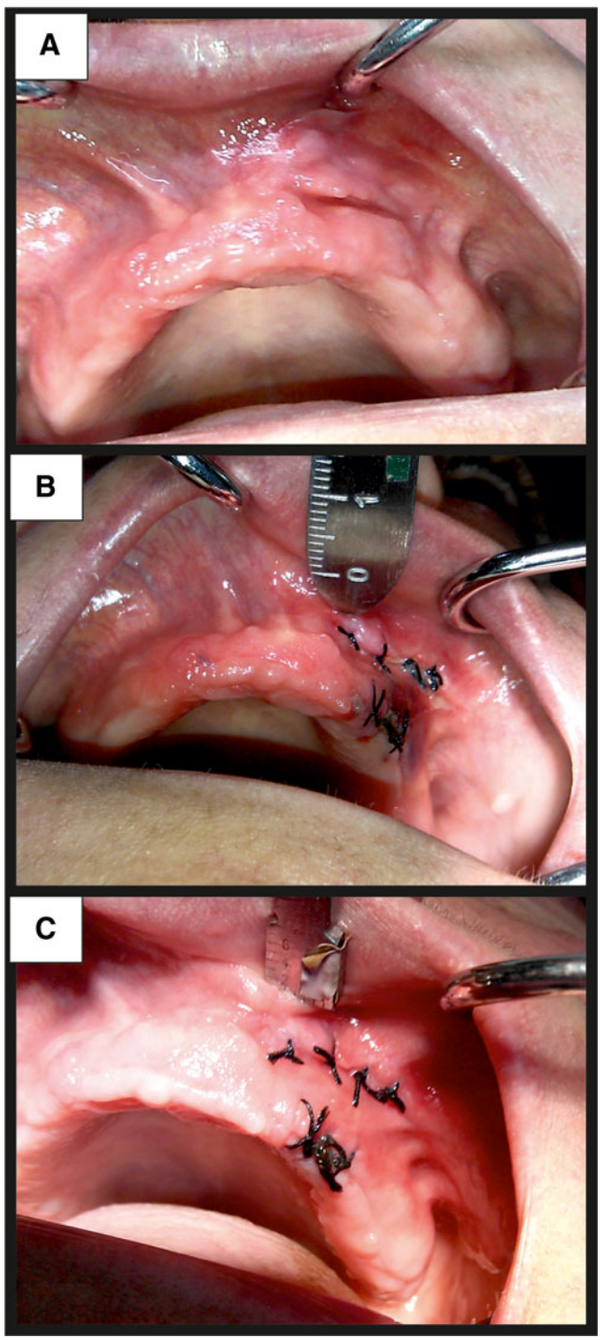

FIG. 3. **(A)** Preoperative image from a patient with epulis fissuratum prior to conventional treatment. **(B)** Postoperative image taken 2 days after conventional treatment. **(C)** Postoperative image taken 7 days after conventional treatment.

all patients received 400 mg of ibuprofen orally every 12 h for 3 days, and used benzydamine HCl plus chlorhexidine gluconate mouthwash (twice daily for 7 days).

Postoperative controls were performed on days 2, 7, 14, and 30. At the control visits, the visual analog scale (VAS) pain scores of the patients on days 2, 7, 14, and 30 were recorded. Total wound surface was measured on days 0 (after excision), 2, 7, 14, and 30 by a ruler according to the Bates–Jensen Wound Assessment Tool[15] by measuring the longest and widest aspect of the wound surface (in cm) using a ruler, and then multiplying the length and width. The extent of edema was determined by obtaining the difference between the measurement on day 0 and the measurements on day 2, 7, 14, and 30 (wound borders during secondary healing were measured in the laser group and borders of edema in the tissue surrounding the suture were measured in the conventional group). Presence of healing, erythema, and suppuration in the surgical area was evaluated by the same physician who was blinded to the patient groups.

Healing in the vertical dimension of the lesion was scored and evaluated as follows: 0 = no protuberance on the surface, 0–1.5 cm^2 peripheral edema, suppuration (–), erythema (–); 1 = up to 1 mm protuberance on the surface, 1.6–3.0 cm^2 peripheral edema, suppuration (–), patchy erythematous wound margins; 2 = 2 mm protuberance on the surface, 3.1–4.5 cm^2 peripheral edema, suppuration (+), half of the wound margin was erythematous; 3 = 3 mm protuberance on the surface, 4.6–6.0 cm^2 peripheral edema, suppuration (+), entire wound margin was erythematous.

Statistical comparison of all data obtained from both groups was performed using the Mann–Whitney *U* test and the Wilcoxon test using the SPSS (version 13.0). A *p* value of <0.05 was considered statistically significant.

Results

Significant differences were determined in the intragroup comparison of the VAS and edema measurements on the control days in both groups ($p = 0.001$ for edema and $p = 0.011$ for VAS in the laser group and $p = 0.002$ and $p = 0.004$ for VAS in the conventional group). No statistically significant difference was found between the VAS scores of the laser and conventional groups (Fig. 1) ($p = 0.744$ on day 2, $p = 0.458$ on day 7, $p = 1.00$ on day 14, and $p = 1.00$ on day 30). On the other hand, it was learned that whereas the conventional group received the prescribed analgesic for the postoperative period, the laser group did not receive it.

The evaluation of the total wound surface, which was performed to determine the extent of edema, included statistical comparison of the groups in terms of the difference between the preoperative and postoperative wound surfaces. No statistically significant difference was observed between the two groups (Fig. 2) $p = 0.206$ on day 2, $p = 0.381$ on day

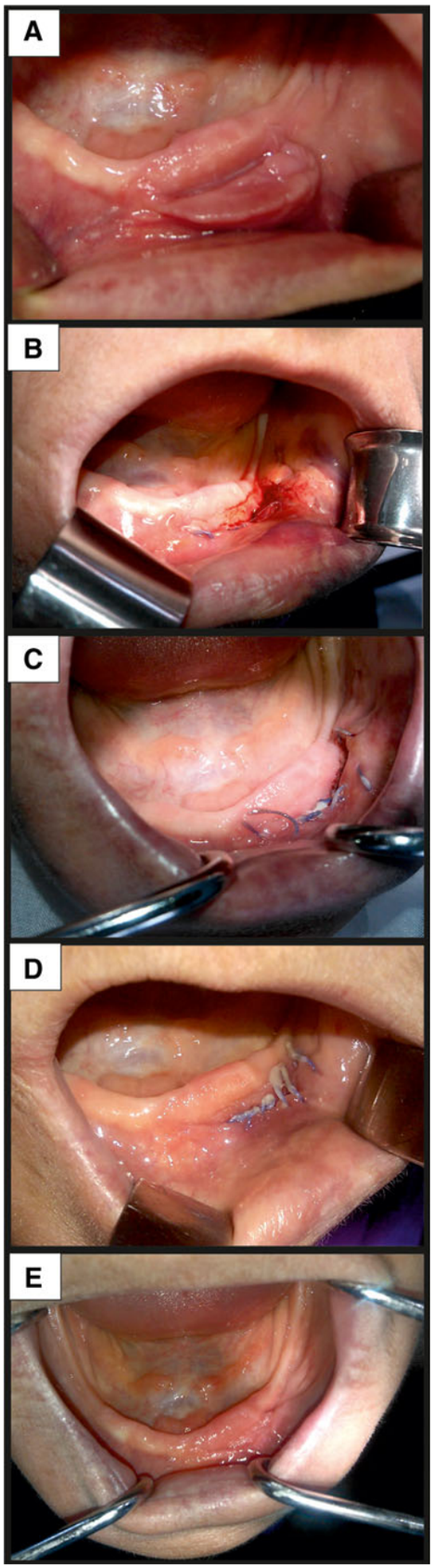

FIG. 4. **(A)** Preoperative image from another patient with epulis fissuratum prior to conventional treatment. **(B)** Postoperative image taken 2 days after conventional treatment. **(C)** Postoperative image taken 7 days after conventional treatment. **(D)** Postoperative image taken 14 days after conventional treatment. **(E)** Postoperative image taken 30 days after conventional treatment.

PHO-2014-3856-ver9-Eroglu_1P.3d 09/09/15 9:47am Page 4

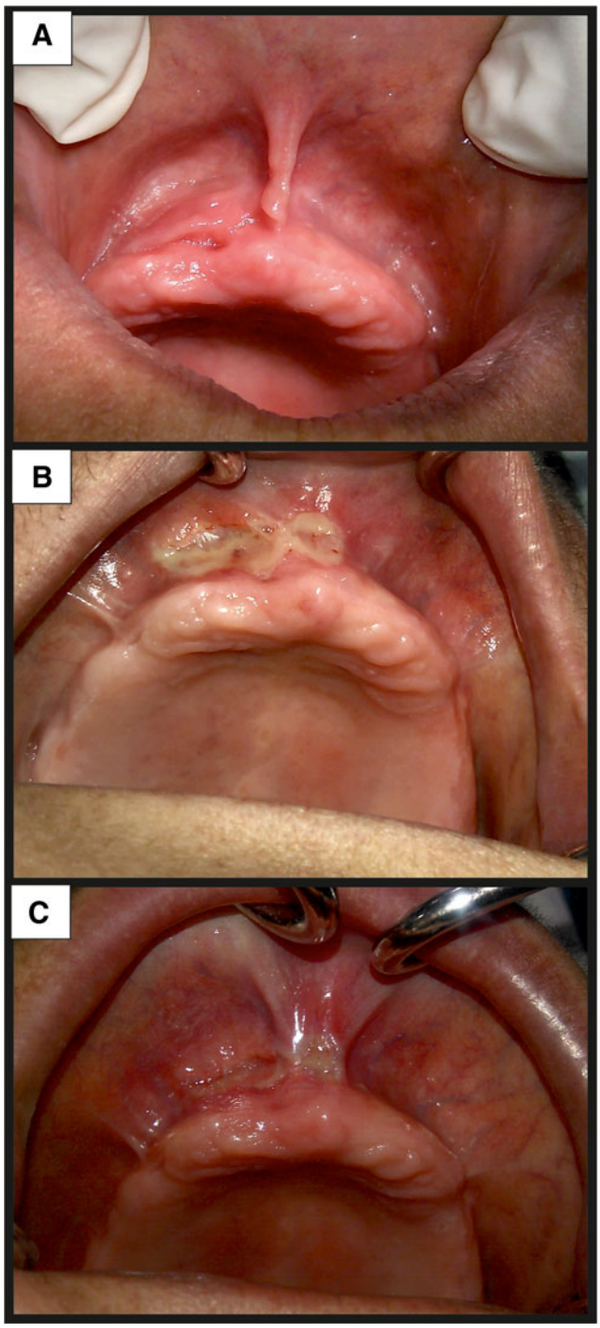

FIG. 5. **(A)** Preoperative image from a patient with epulis fissuratum prior to erbium, chromium:yttrium-scandium-gallium-garnet (Er,Cr:YSGG) laser treatment. **(B)** Postoperative image taken 2 days after Er,Cr:YSGG laser treatment. **(C)** Postoperative image taken 7 days after Er,Cr:YSGG laser treatment.

7, $p=0.776$ on day 14, and $p=0.133$ on day 30). The preoperative and postoperative images of the patient at various intervals are shown in Figures 3–6. F3–F6 ▶

Evaluation of the healing revealed that whereas the rate of score 0 was 59% in the conventional group on postoperative day 2, it was 82% in the laser group. Scores 2 and 3 were not present but the rate of score 1 was 18% in the laser group on day 2. In the conventional group, the rates of scores 1, 2, and 3 on day 2 were 23%, 9%, and 9%, respectively. On day 7, any wound surface to be scored was not observed in the laser group, whereas it was scored as 1 at a rate of 4.5% in the conventional group. Neither group had a wound surface to be scored on days 14 and 30.

Postoperative patient comfort and clinical outcomes including postoperative bleeding, wound recovery, lack of suture requirement, and decreased need for local anesthesia were better in the laser group than in the conventional group. Neither suppuration nor serious erythema was observed in the laser group. Relapse was observed in one patient in the laser group after 3 months, because of the reuse of an inappropriate denture. One patient in the conventional group developed a postoperative hematoma.

Discussion

In routine practice, the scalpel is frequently preferred to alternate methods for soft tissue surgeries by oral and maxillofacial surgeons. In addition to being practical, fast, and inexpensive, neither the surgeon nor the patient needs protective equipment to avoid radiation while using the traditional scalpel method. However, despite its advantages, which include accuracy, precision, sensitive work, and minimal tissue injury, the scalpel is associated with disadvantages, including increased edema caused by extravasation from blood and lymph vessels, a prolonged recovery period, and loss of vestibular depth.[16,17] The major disadvantage associated with laser surgery is absolute thermal damage in the tissue.[9]

The major advantages of the Er,Cr:YSGG laser include less bleeding and swelling and, notably, less pain because of less histamine release. In fact, some soft tissue surgeries (e.g., small biopsies), may be performed without using a local anesthetic and without causing pain. Although the present study showed no statistically significant difference between the groups, the VAS score in the laser group was lower than that of the conventional group. Interestingly, none of the patients in the laser group received analgesics. The expected result is a higher sensation of pain in the wounds allowed secondary healing than in the primarily closed wounds, because free nerve ends are exposed in those allowed secondary healing. Postoperatively, in the open oral wounds, nutrition and cheek-mouth movements may cause pain in the lesion area.[18] However, pain in the laser group might have been felt less than in the conventional group, in which patients received analgesic, because of the absence of serious injury in the tissue allowed secondary healing after Er,Cr:YSGG laser surgery[7] and thereby a lower amount of inflammatory mediators (prostaglandins, leukotrienes, bradykinin) secreted from the tissue. Moreover, we think that pressure by peripheral edema around the sutured tissue might cause pain. The results within this entire process are a comparison between the conventional group that received analgesic and the laser group that did not. In this respect, laser is undisputedly superior in causing less postoperative pain.

There are studies that suggest that surgeries performed with the Er,Cr:YSGG laser result in better postoperative wound healing than surgeries performed with other types of lasers. In patients undergoing surgery with Er,Cr:YSGG lasers, it appears that their recovery time significantly

PHO-2014-3856-ver9-Eroglu_1P.3d 09/09/15 9:47am Page 5

shortens.[19] In one study, the Er,Cr:YSGG laser displayed faster wound healing and re-epithelization in soft tissue surgery than did the CO_2 laser after upper lip frenectomy.[20] Likewise, studies of surgery performed with the Er,Cr:YSGG laser have reported improved healing, with a faster recovery time and less trauma to the target tissue than with traditional surgical modalities.[21,22] Luomanen[23] compared incisions made by a scalpel and laser, and reported a delay in capillary proliferation at laser-treated sites during the early healing phase. In addition, other studies have reported denser inflammatory cell infiltration in laser-induced wounds than in scalpel-induced wounds.[16,17]

In the present study, the total wound surface was lower and the recovery period was better in the laser group than in the conventional group, which is consistent with the literature. The clinical outcomes that were measured to assess the recovery period were postoperative bleeding, wound recovery, lack of suture requirement, lack of analgesic intake, and decreased need for local anesthesia. The use of Er,Cr:YSGG laser was observed to provide physicians with a clear view of the surgical field without bleeding, enabling them to save time and effort regarding anesthesia, suture, and bleeding control, and facilitating cooperation and motivation of the patient.

Contrasting laser studies have demonstrated striking results and have even found the scalpel to be more tissue-friendly than the CO_2 and diode lasers in soft tissue surgeries. Among these studies, an animal study comparing the Er,Cr:YSGG laser, scalpel, and diode laser reported that the diode laser caused more tissue injury than the Er,Cr:YSGG laser and scalpel. Tumor necrosis factor-α (TNF-α), a proinflammatory cytokine, was overexpressed in tissues, particularly on the 1st postoperative day, in a group that was exposed to the diode laser.[6] Another study reported that CO_2 laser-induced tissue injury was worse than scalpel-induced tissue injury.[24] The type of laser and the method chosen in surgical procedures had a direct effect on recovery. Interestingly, in a rat study conducted in recent years, it was observed that both Er,Cr:YSGG laser and scalpel wounds healed similarly at the histological level.[25]

Under these circumstances, the question of ''how could healing be better or equal at the end of an intervention where thermal injury is in question'' emerges. It has been demonstrated that anti-inflammatory mechanism is inhibited, cellular stimulation is induced, tissue regeneration is accelerated, wound healing is better, and pain and edema are decreased in low-level laser applications.[26,27] Starting from this point, if we express an opinion on how healing would be better following a thermal injury, it seems that positive stimulating effect of laser on adjacent tissues during laser surgery is likely to accelerate healing period both by suppressing inflammatory pathway and by contributing to regeneration (by enabling angiogenesis,

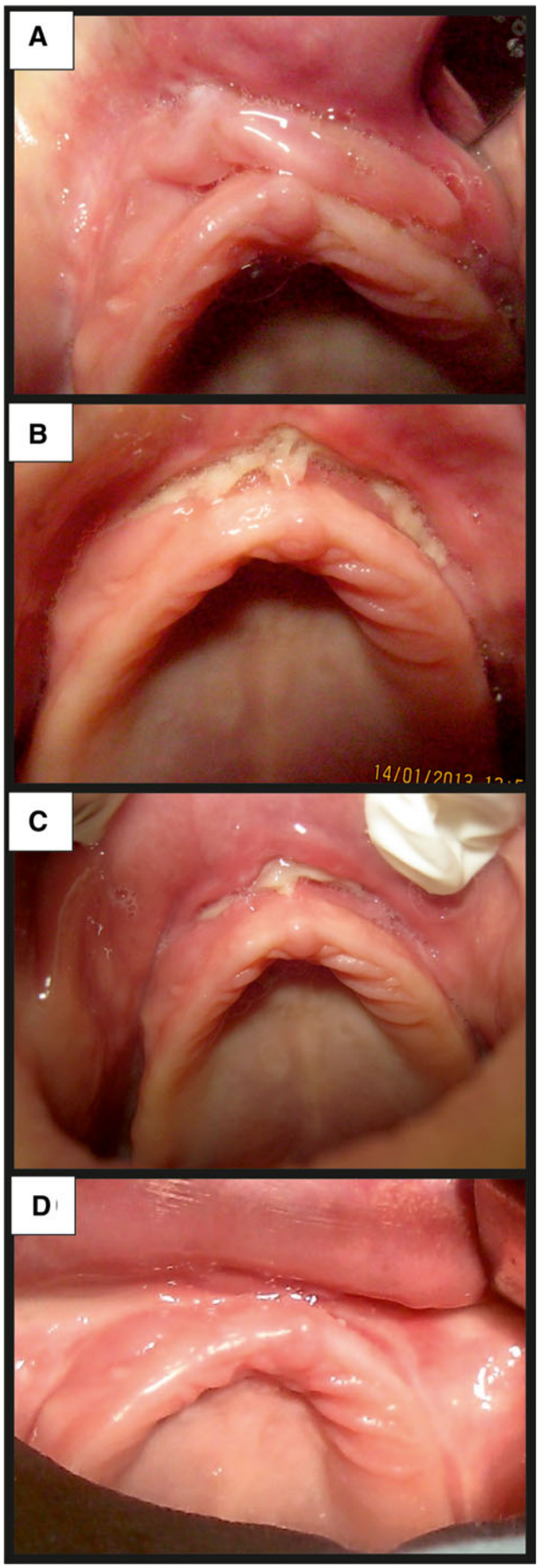

FIG. 6. **(A)** Preoperative image from the other patient with epulis fissuratum prior to erbium, chromium:yttrium-scandium-gallium-garnet (Er,Cr:YSGG) laser treatment. **(B)** Postoperative image taken 2 days after Er,Cr:YSGG laser treatment. **(C)** Postoperative image taken 7 days after Er,Cr:YSGG laser treatment. (D) Postoperative image taken 30 days after Er,Cr:YSGG laser treatment.

PHO-2014-3856-ver9-Eroglu_1P.3d 09/09/15 9:47am Page 6

collagen deposition, fibroblast proliferation and tissue re-epithelization).[28]

In a study conducted on rodents, findings related to the presence of epithelial migration and maturation and regular collagen fibrils by the 3rd day and complete improvement by the 11th day via photobiomodulation property of low-level laser therapy were reported in formocresol-induced oral mucosa ulcers.[29] Dawood et al.[30] reported duration for the complete epithelization to be between 7 and 9 days when biostimulation was applied to oral wounds by diode laser. Laser therapy application in the 1st day of the wound formation provides an increase in the polymorphonuclear neutrophils and mast cells.[31] This increases the number of blood vessels and inflammatory process by triggering vasodilatation, and thereby accelerates healing.[29]

According to our knowledge, there is no study in the literature scientifically comparing the behaviors of open and closed oral wounds. After a surgery in which a scalpel is used, cauterization, laser coagulation, or an antihemorrhagic agent is needed for bleeding control in a study in which the wound will be left open without suturing. In that case, however, it is mandatory to consider the alterations in the wounds caused by these approaches. In addition, if the wounds are left open without any application, it will not be ethical, as there will be bleeding problems in large lesions; these types of cases were also present in our study. In this circumstance, it is mandatory to use sutures and the disadvantages (high VAS scores because of suturing and scar formation) arising from suturing will occur in such a study.

If an explanation needs to be made about the lack of difference in the evaluation of wound surface in cm^2, an ideal measurement, unfortunately, could not be performed because such studies make comparison between primarily closed surfaces and surfaces allowed secondary healing. This is the limitation of the present study and, therefore, we accepted the edema spreading beneath the tissue as a wound surface, to obtain a value close to the real wound size. Perhaps a likely difference between wound surface measurements could have been exposed if a different method had been used for evaluation.

In the present study, the reason for preferring only the epulis fissuratum lesions by excluding all other soft tissue lesions was that most oral lesions have different characteristics. Epulis fissuratum is a lesion that mostly exhibits fibrotic structure,[32,33] and we thought that studying one type of lesion would be advantageous to provide standardization of the lesion type.

Another issue that should be clarified in the present study is the lack of a control group. It does not seem to be feasible to form a control group in a study aiming at elimination of pathology. Ultimately, each performed treatment type will direct the study as a method, regardless of the method of choice in the control group.

We observed over the course of the study that although laser is a quite expensive method compared with scalpel, it has substantial advantages in terms of cost, because of material utilized in the long term (local anesthetic, analgesic, hemostatic agent, scalpel, suture), in terms of time both for the patient and the physician, because of the decreased number of patient visits, and in terms of clinical success, because of healing without complication, absence of suture-related extratissue trauma (absence of trauma resulting from all interventions for hemostatic purposes on the wound surface that is allowed secondary healing), and high preoperative patient motivation and postoperative patient satisfaction.

In addition to the other advantages mentioned in the literature, the fact that the patients did not require suture removal or a second surgical procedure to provide vestibular depth in the laser group of the present study provided us with gain in terms of time and clinical burden.

Conclusions

In conclusion, we observed that epulis fissuratum removal surgery performed with the Er,Cr:YSGG laser improved clinical outcomes compared with the conventional method, resulting in better intraoperative and postoperative patient comfort and wound healing. The Er,Cr:YSGG laser is a good instrument that can be preferred for soft tissue surgery, and that promise a clean surgery without complication, as well as a painless healing period of good quality.

Author Disclosure Statement

No competing financial interests exist.

References

1. Tamarit-Borrás M, Delgado-Molina E, Berini-Aytés L, Gay-Escoda C. Removal of hyperplastic lesions of the oral cavity. A retrospective study of 128 cases. Med Oral Patol Oral Cir Bucal 2005;10:151–162.
2. Niccoli-Filho W, Neves ACC, Penna LAP, Seraidarian PI, Riva R. Removal of epulis fissuratum associated to vestibuloplasty with carbon dioxide laser. Lasers Med Sci 1999;14:203–206.
3. Lewandrowski KU, Lorente C, Schomacker KT, Flotte TJ, Wilkes JW, Deutsch TF. Use of Er:YAG laser for improved plating in maxillofacial surgery: comparison of bone healing in laser and drill osteotomies. Lasers Surg Med 1996; 19:40–45.
4. Goharkhay K, Moritz A,Wilder-Smith P, et al. Effects on oral soft tissue produced by a diode laser in vitro. Lasers Surg Med 1999;25:401–406.
5. Liboon J, Funkhouser W, Terris DJ. A comparison of mucosal incisions made by scalpel, CO2 laser, electrocautery, and constant-voltage electrocautery. Otolaryngol Head Neck Surg 1997;116:379–385.
6. Jin JY, Lee SH, Yoon HJ. A comparative study of wound healing following incision with a scalpel, diode laser or Er, Cr:YSGG laser in guinea pig oral mucosa: A histological and immunohistochemical analysis. Acta Odontol Scand 2010;68:232–238.
7. Wang X, Ishizaki NT, Suzuki N, Kimura Y, Matsumoto K. Morphological changes of bovine mandibular bone irradiated by Er,Cr:YSGG laser: an in vitro study. J Clin Laser Med Surg 2002;20:245–250.
8. Ekworapoj P, Sidhu SK, McCabe JF. Effect of different power parameters of Er,Cr:YSGG laser on human dentine. Lasers Surg Med 2007;22:175–182.
9. Cercadillo-Ibarguren I, España-Tost A, Arnabat-Domínguez J, Valmaseda-Castellón E, Berini-Aytes L, Gay-Escoda C. Histologic evaluation of thermal damage produced on soft tissues by CO2, Er, Cr:YSGG and diode lasers. Med Oral Patol Oral Cir Bucal 2010;15:e912–918.
10. Ishikawa I, Aoki A, Takasaki AA, Mizutani K, Sasaki KM, Izumi Y. Application of lasers in periodontics: true innovation or myth? Periodontol 2000 2009;50:90–126.

PHO-2014-3856-ver9-Eroglu_1P.3d 09/09/15 9:47am Page 7

11. Cobb CM Lasers in periodontics: a review of the literature. J Periodontol 2006;77:545–564.
12. Wigdor HA, Walsh JT, Jr, Featherstone JD, Visuri SR, Fried D, Waldvogel JL. Lasers in dentistry. Lasers Surg Med 1995;16:103–133.
13. Luomanen M, Meurman JH, Lehto VP. Extracellular matrix in healing CO2 laser incision wound. J Oral Pathol 1987;16:322–331.
14. White JM, Goodis HE, Rose CL. Use of the pulsed Nd: YAG laser for intraoral soft tissue surgery. Lasers Surg Med 11:455–461.
15. Harris C, Bates-Jensen B, Parslow N, Raizman R, Singh M, Ketchen R. Bates-Jensen wound assessment tool: pictorial guide validation project. J Wound Ostomy Continence Nurs 2010;37:253–259.
16. Pogrel MA, Yen CK, Hansen LS. A comparison of carbon dioxide laser, liquid nitrogen cryosurgery, and scalpel wounds in healing. Oral Surg Oral Med Oral Pathol 1990;69:269–273.
17. Schaffer CJ, Reinisch L, Polis SL, Stricklin GP. Comparisons of wound healing among excisional, laser-created, and standard thermal burns in porcine wounds of equal depth. Wound Repair Regen 1997;5:52–61.
18. Ettlin DA, Hitz T, Ramel C, et al. Quantitative sensory testing of intraoral open wounds. Int J Oral Maxillofac Surg 2013;42:401–405.
19. Pavelec V, Polenik P. Use of Er;Cr:YSGG versus standard lasers in laser assisted uvulopalatoplasty for treatment of snoring. Laryngoscope 2006;116:1512–1516.
20. Pié-Sánchez J, España-Tost AJ, Arnabat-Domínguez J, Gay-Escoda C. Comparative study of upper lip frenectomy with the CO_2 laser versus the Er, Cr:YSGG laser. Med Oral Patol Oral Cir Bucal 2012;17:e228–232.
21. Walinski CJ. Irritation fibroma removal: a comparison of two laser wavelengths. Gen Dent 2004;52:236–238.
22. Olivi G, Costacurta M, Maturo P, Docimo R. Removal of fibrous epulis with Er, Cr:YSGG laser: case report. Eur J Paediatr Dent 2007;8:149–152.
23. Luomanen M. A comparative study of healing of laser and scalpel incision wounds in rat oral mucosa. Scand J Dent Res 1987;95:65–73.
24. Ryu SW, Lee SH, Yoon HJ. A comparative histological and immunohistochemical study of wound healing following incision with a scalpel, CO_2 laser or Er, Cr:YSGG laser in the guinea pig oral mucosa. Acta Odontol Scand 2012;70:448–454.
25. Perussi LR, Pavone C, de Oliveira GJ, Cerri PS, Marcantonio RA. Effects of the Er,Cr:YSGG laser on bone and soft tissue in a rat model. Lasers Med Sci 2012;27:95–102.
26. Coluzzi DJ, Convissar RA. Lasers in clinical dentistry. Dent Clin North Am 2004;48:1061.
27. Boschi ES, Leite CE, Saciura VC, et al. Anti-inflammatory effects of low-level laser therapy (660 nm) in the early phase in carrageenan-induced pleurisy in rat. Lasers Surg Med 2008;40:500–508.
28. Zhang F, Lei MP, Oswald TM, et al. The effect of vascular endothelial growth factor on the healing of ischaemic skin wounds. Br J Plast Surg 2003;56:334–341.
29. de Carvalho FB, Andrade AS, Rasquin LC, et al. Effect of laser (λ 660 nm) and LED (λ 630 nm) photobiomodulation on formocresol-induced oral ulcers: a clinical and histological study on rodents. Lasers Med Sci 2015;30:389–396.
30. Dawood MS, Al-Habib MF, Salman SD. A histological study of the effect of low level diode laser therapy on wound healing. Nahrain Univ Coll Eng J 2009;12, 80–88. ◀AU2
31. Pereira MC, de Pinho CB, Medrado AR, Andrade Z de A, Reis, SR. Influence of 670 nm low-level laser therapy on mast cells and vascular response of cutaneous injuries. J Photochem Photobiol B 2010;98:188–192.
32. de Arruda Paes-Junior TJ, Cavalcanti SC, Nascimento DF, et al. CO_2 laser surgery and prosthetic management for the treatment of epulis fissuratum. ISRN Dent 2011;2011:282361.
33. Canger EM, Celenk P, Kayipmaz S Denture-related hyperplasia: a clinical study of a Turkish population group. Braz Dent J 2009;20:243–248.

Address correspondence to:
Cennet Neslihan Eroglu
Yuzuncu Yil Universitesi
Dis Hekimligi Fakultesi
Kampus, 65080 Van
Turkey

E-mail: neslihanakca2003@yahoo.com

AUTHOR QUERY FOR PHO-2014-3856-VER9-EROGLU_1P

AU1: Please provide authors' degrees where they are missing.
AU2: Please check reference. Not in PubMed.