Check for updates

Received: 16 May 2021 | Revised: 30 June 2021 | Accepted: 2 July 2021

DOI: 10.1111/and.14189

ORIGINAL ARTICLE

First International Journal of Andrology
ANDROLOGIA
WILEY

Evaluation of protective effects of gallic acid on cisplatin-induced testicular and epididymal damage

Fikret Altındağ[1] | İsmet Meydan[2]

[1]Department of Histology and Embryology, Van Yüzüncü Yıl University, Van, Turkey

[2]Department of Biochemistry, Van Vocational Higher School of Healthcare Studies, Van Yüzüncü Yıl University, Van, Turkey

Correspondence
Fikret Altındağ, Department of Histology and Embryology, Faculty of Medicine, Van Yüzüncü Yıl University, Van, Turkey
Email: altindagfikret@gmail.com

Abstract

Cisplatin is an effective chemotherapeutic drug used to treat many types of tumours. However, it may cause male reproductive toxicity. Gallic acid exhibits beneficial effects such as antioxidant, anti-inflammatory and antitumor. The current study investigated the beneficial effects of gallic acid against testis and epididymis toxicity induced by cisplatin. Male rats were divided into 4 groups as follows ($n = 7$): Control, cisplatin (a single dose of 8 mg/kg), Gallic acid (50 mg/kg) and cisplatin +Gallic acid groups. Testis was examined morphometrically by stereological methods. In addition, apoptosis, DNA damage, oxidative stress parameters in testis and testosterone in serum were measured. Epididymis was histopathologically evaluated. As a result, a significant decrease was observed in the number of spermatogonia, Leydig and Sertoli cells, testicular volume, height of germinal epithelial, Bcl-2 immunopositive cell number, activity of CAT, GSH and SOD enzymes and serum testosterone levels compared with the cisplatin group control group, while a significant increase was observed in the number of Caspase-3, Bax and 8-OHdG immunopositive cells and the MDA levels. However, Gallic acid significantly restored these parameters. Our study reveals that Gallic acid may improve Cisplatin-induced male reproductive toxicity by reducing oxidative stress, suppressing apoptosis and DNA damage and restoring structural and functional deterioration.

KEYWORDS

apoptosis, cisplatin, DNA damage, gallic acid, testis

1 | INTRODUCTION

Cisplatin (CP) is a powerful antineoplastic drug widely used to treat various cancers such as bladder, lung, and testis cancer (Azarbarz et al., 2020). The anti-tumour effect of CP, a DNA-alkylating molecule, prevents the replication and transcription of DNA by breaking the DNA double strands (Ahmed et al., 2011). However, CP has side effects such as ototoxicity, nephrotoxicity, neurotoxicity and testicular toxicity, as well as significant anti-tumour effects (Elrashidy & Hasan, 2020). It has been determined that oxidative stress, inflammation and ischaemic injury are pathological conditions caused by CP toxicity in tissues (Eren et al., 2020). The testis has become the target of chemotherapeutic agents due to the spermatogenesis and spermiogenesis in which testicular cell division and morphological changes occur, and these agents can easily damage the testis (Ceylan et al., 2020). The permanent side effects of CP cause disruption of the Sertoli cell and seminiferous epithelium that results in the impairment of spermatogenesis (Whirledge et al., 2015). CP causes Leydig cell dysfunction leading to impaired testosterone secretion (El-shafaei et al., 2018). In addition, CP causes epididymal toxicity by resulting in decreased epididymal sperm count (Kohsaka et al., 2020). Thus, infertility occurs in parallel with CP application (Mercantepe et al., 2018). Although the underlying mechanism of CP toxicity on the testis and epididymis is not fully understood, one of

 © 2021 Wiley-VCH GmbH

its basic mechanisms is estimated to be related to its induction of reactive oxygen species (ROS) production and the decrease in the level of testicular antioxidants (Eren et al., 2020). Thus, the use of natural products that can scavenge ROS with anti-oxidative capacity is gradually increasing in the treatment of diseases and protection of tissues against intoxication of toxic substances. Various cytoprotective, antioxidant and functional foodstuffs have been applied to reduce or prevent CP toxicity (Kohsaka et al., 2020).

Gallic acid (GA), a polyphenol compound found in many vegetables and fruits such as bananas, strawberries, sumac, green tea and oak bark, exhibits antioxidant, anti-inflammatory, anticancer and antiviral effects (Zhu et al., 2019). GA that is widely used in medicine, cosmetics and foods attracts the attention of researchers because of its useful effects (Dehghani et al., 2020). The antioxidant effect of GA ensures that the functions of biological systems are carried out properly, and the balance between the oxidant and antioxidant mechanism is maintained (Shruthi et al., 2018). Also, its anti-inflammatory effect prevents or reduces the expression of inflammatory molecules and, thus, can be used in the treatment of inflammatory diseases (Kim et al., 2006). It has been reported that GA exhibits protective effects against cyclophosphamide-induced toxicity in testis and epididymis (Oyagbemi et al., 2016). Previous studies have shown that GA can protect the reproductive system of rats incumbent on manganese and AFB1-induced oxidative and inflammatory damage (Owumi et al., 2020). It has been also reported that GA exhibits curative effects on CP-induced nephrotoxicity and bone marrow genotoxicity (Akomolafe et al., 2014; Dehghani et al., 2020; Shruthi et al., 2018).

It is very important to protect male reproductive health against CP toxicity in patients undergoing chemotherapy. However, no adequate study has been found on the effects of GA on CP-induced testis and epididymis toxicity. Therefore, in our study, we investigated the mechanism underlying the effects of GA in CP-induced male reproductive toxicity in detail by stereological immunohistochemical and biochemical evaluation.

2 | MATERIAL AND METHOD

2.1 | Chemicals and antibodies

Caspase-3 (sc-56048), Bax (sc-20067), Bcl-2 (sc-7382) and 8-OHdG (sc-393871) were obtained from Santa Cruz Biotechnology. GA (CAS: 149–91–7) was obtained from Sigma Aldrich, and CP was obtained from Koçak Farma company (İstanbul, Turkey). Ultravision detection system large volume anti-polyvalent HRP (IHC detection Kit) and other chemicals required for immunohistochemical examination were obtained from Thermo Fisher Scientific (Kalamazoo, USA).

2.2 | Experimental animals and drug treatment

The protocol of our study was approved by Van Yuzuncu Yil University Animal Experiments Local Ethics Committee (decision number: 2021/02-25), and all methods were performed to the guidelines of the committee. In this study, a total of 28 adult male Wistar rats weighing 200 ± 20 g were used, and the animals were obtained from the Van Yüzüncü Yıl University Experimental Animals Research and Application Center. Rats were randomly divided into four groups ($n = 7$). The control (C) group was received 0.5 ml saline by intraperitoneal (IP). CP group was applied a single dose of 8 mg kg^{-1} day^{-1} CP (IP) on the 5th day of study. GA group was received 50 mg/kg GA by gastric gavage for 10 days. CP +GA group was received 50 mg/kg GA by gavage for 10 days and a single dose of 8 mg/kg CP (IP) on the 5th day of the study. The doses of CP and GA were designed according to a previous study (Abarikwu et al., 2020; Tomar et al., 2017). Rats were housed under standard conditions of temperature (25 ± 2°C), relative humidity (50 ± 10%) and 12 hr light/12 hr dark cycle. The animals were fed with a standard pellet diet (ad libitum).

2.3 | Stereological analysis

To evaluate stereological parameters, testis was fractionated into fractions (f) by the systematic random sampling rules (Cahill et al., 1996). For this, the testis was divided into four equal parts (f1 = 1/4). One of the four pieces of the testis was randomly selected and then embedded in paraffin. 4 μm thickness sections were cut for stereological examination. The first section was taken randomly, and the next sections were taken every 50 steps (f2 = 1/50). An average of 10–13 sections was taken. After the sections taken were stained with haematoxylin-eosin (H-E), examined by light microscopy (Olympus BX53) using a microscopy camera (Olympus DP27) and microscope imaging systems (Olympus CellSens Entry).

2.3.1 | Calculation of the total number of cells

The physical dissector counting method was used to calculate the total number of spermatogonia, Sertoli and Leydig cells according to previous studies (Altindağ & Özdek, 2021). The following formula was used to calculate the total cell number:

$N = N_v \times V_{final}$where N_v is the numerical density of the cell of interest (cells/unit volume) and V_{final} is the total volume of the testis (Gundersen, 1986; Mayhew & Gundersen, 1996).

2.3.2 | Estimation of the total volume

The point-counting method of the Cavalieri principle was used to calculate the total volume of the testis, germinal epithelial volume, and interstitial volume. For this, the total numbers of points hitting all testis, germinal epithelial and interstitial area were counted using the point-counting probe. The following formula was used to calculate the volume:

$$V_{ref} = \sum P \times a/p \times h$$

TABLE 1 Effect of GA on stereological parameters in CP-induced rats

Groups	The total number of spermatogonia	The total number of Sertoli cells	The total number of Leydig cells	The total volume of testis (mm^3)	The total volume of seminiferous tubule (mm^3)	The total volume of interstitial (mm^3)	Height of germinal epithelial (μm)
Control	10,128,396 ± 980602[b]	6,986,982 ± 218182[b]	4,668,402 ± 341247[b]	1,484 ± 85[b]	1,169 ± 67[b]	294 ± 27	79.6 ± 7.4[b]
CP	8,161,542 ± 570060[a]	58,660,787 ± 472222[a]	3,883,100 ± 227340[a]	1,241 ± 70[a]	956 ± 45[a]	276 ± 47	66.4 ± 5.3[a]
CP + GA	9,331,420 ± 456670[b]	6,678,004 ± 639402[b]	4,457,787 ± 369579[b]	1,397 ± 23[b]	1,106 ± 67[b]	284 ± 21	76.3 ± 4.3[b]
GA	10,271,330 ± 635569[b]	6,768,161 ± 645778[b]	4,749,709 ± 384872[b]	1,477 ± 45[b]	1,173 ± 86[b]	303 ± 32	83.1 ± 8.6[b]

Note: Values are expressed as means ± *SD*. Significant differences as compared with the Control group at [a]$p < 0.05$, Significant differences as compared with the CP group at [b]$p < 0.05$.

where '*V*' is the volume of the structure, '∑*P*' is the total number of points hitting the structure, 'a/p' is the area covered by one point and 'h' is the height of dissector. To calculate the total volume of the tissue, the reference volume is multiplied by the fraction ratios (f1 and f2) and the shrinkage rate. After the histological tissue processing stages, the volume of tissue is usually shrunk. The testis shrinkage rate was calculated according to previous studies (Altindağ & Özdek, 2021).

2.3.3 | Estimation of the height of the germinal epithelium

The height of the germinal epithelium (HGE) was estimated according to previous studies (Altindağ & Özdek, 2021). For this, the following formulas were used:

$$S_{v(epithelium/ref)} = 2 \times \sum I / (\sum P \times I/p)$$

$$HGE = V_v(epithelium/ref)) / S_v(epithelium/ref)$$

where '∑*I*' is the total number of intersection points of the luminal surface of the epithelium and the test lines, '∑*P*' is the total number of points hitting testis and 'I/p' is the length of a test line. The total surface area is calculated by multiplying the surface density by the total volume (Altindağ & Özdek, 2021; Noorafshan, 2014).

2.4 | Histological preparation

At the end of the experiment, rats were anaesthetised by xylazine (10 mg/kg) and ketamine (50 mg/kg) IP. For stereological, immunohistochemical and histological examination, the testis and epididymis tissues were removed by an incision made from the scrotal region and fixed in 10% buffered formalin. Testis and epididymis were embedded in paraffin after the tissue processing stages. Sections of 4 μm thickness taken from paraffin blocks were stained with haematoxylin-eosin (H&E).

The histological examination was made according to the Johnsen score (Johnsen, 1970) For this, 15–20 areas were evaluated by random sampling in 8–10 sections taken from each animal in the groups.

2.5 | Immunohistochemical preparation

The sections of 4 μm thickness taken from paraffin blocks were deparaffinised and dehydrated. After sections were incubated in 3% Hydrogen peroxide (H_2O_2), in citrate buffer (ph 6.1), in Ultra V Block, in antibodies of Caspase-3 (1:50), Bax (1:50), Bcl-2 (1:50), and 8-OHdG (1:50), in Biotinylated Goat Anti-Polyvalent and Streptavidin–peroxidase conjugate respectively. Diaminobenzidine (DAB) was used as a chromogen and then stained with Mayer's haematoxylin. Cell numerical density was estimated by counting Caspase-3, Bax, Bcl-2 and 8-OHdG positive cells using the physical dissector counting method, which is a stereological method by a light microscope

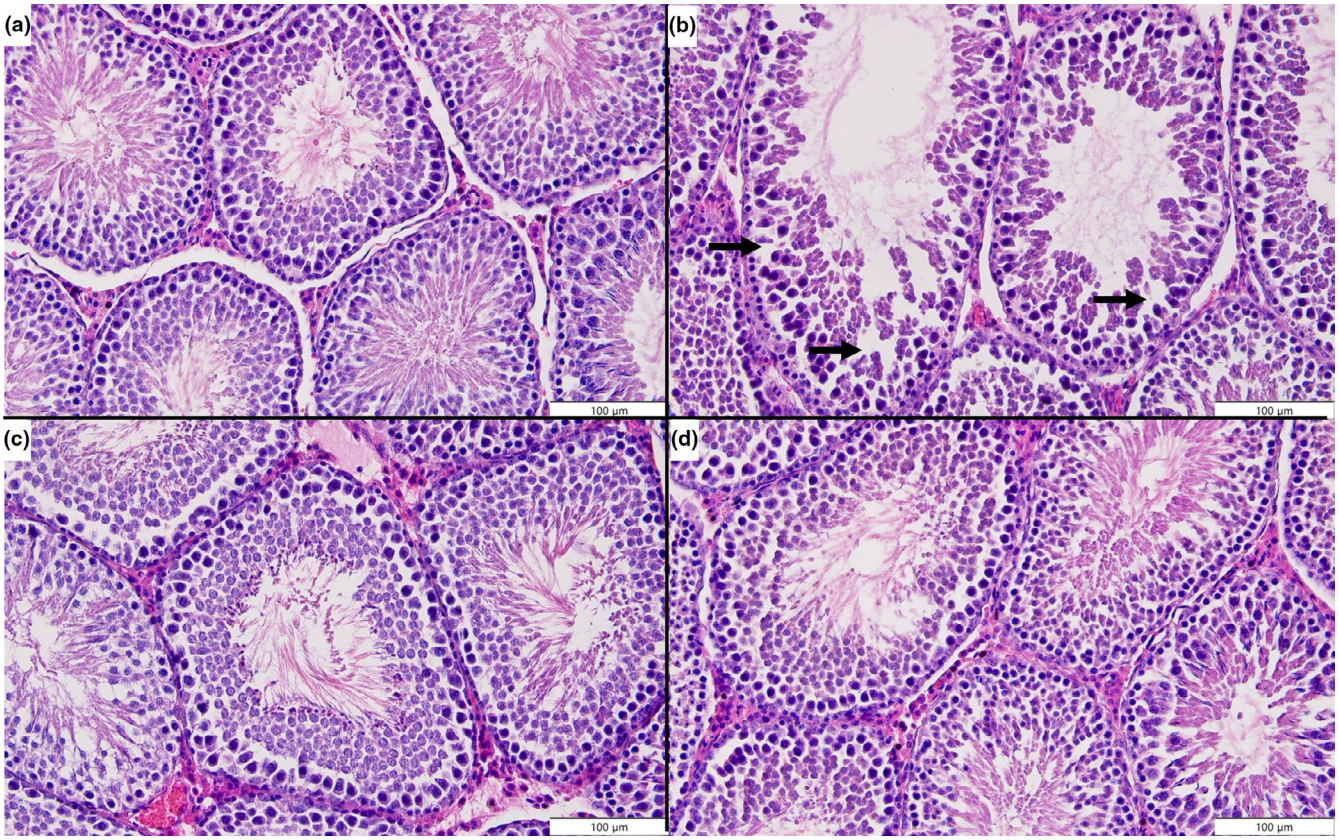

FIGURE 1 Light microscope images of testis stained by haematoxylin and eosin (H-E) staining. x200. Testis has normal histological architecture in control (a) and GA (d) groups. In the CP group (b), atrophy (arrow) in the seminiferous tubules, loss of germ cells and a decrease in sperm count in the lumen of the testis was observed. GA improved testicular structural deterioration caused by CP (c)

(Olympus BX53) and cellSens Software imaging systems (Olympus).

The formula below was used for this:$Nv = \frac{\sum Q^-}{\sum P \times a/frame \times h}$where $\sum Q^-$ is the total number of immunopositive cells counted in all the dissector, $\sum P$ is the total number of counting frames, a/frame is the area of counting frame and h is the height of dissector.

2.6 | Measurements of serum testosterone levels

At the end of the study, blood samples taken from the heart with an injector were centrifuged at +4°C at 3,000 rpm for 10 min. Serum testosterone was evaluated in an autoanalyzer (Abbott Architect ci16200,) using commercial kits (Abbott Architect 2nd Generation Testosterone Reagent Kit).

2.7 | Measurement of parameters related to oxidative stress in testis

It was measured the activity of CAT, GSH and SOD enzymes to evaluate the antioxidant and was measured the MDA levels to determine the lipid peroxidation. For this, testis tissues were homogenised by a homogeniser. Homogenates were centrifuged at 2000–3000 rpm, +4°C for 20 min. For MDA measurement, 50 ml of TBA and 50 ml of TCA were prepared as reagents. 250 µl sample taken from the supernatant was mixed with 125 µl TCA of 20%. The preparing mixture was centrifuged at 15,000 rpm for 20 min. 300 µl of supernatant was mixed with 200 µl TBA. It was incubated for 60 min. The mixtures obtained were evaluated in a 535 nm UV spectrophotometer (Buege & Aust, 1978; Dubovskiy et al., 2008). Determination of CAT enzyme activity was made in an ELISA device using a commercial kit (BT Lab no: E0869 Ra). 40 µl sample, 10 µl CAT antibody and 50 µl streptavidin were added. It was incubated at 37°C for 1 hr. After incubation, it was washed 5 times with a wash solution to remove unbound components. After the washing process was completed, 50 µl of chromogen A solution and 50 µl of chromogen B solution were added. Subsequently, it was incubated at 37°C for 10 min. After incubation, 50 µl stop solution was added to it and the blue colour turned yellow with the acid in the stop solution. The optical density of the resulting yellow colour was measured at 450 nm, and the CAT concentrations in the samples were determined (Dubovskiy et al., 2008; Lartillot et al., 1988). GSH (Beutler et al., 1963) and SOD (Sun et al., 1988) were similarly performed according to previous studies.

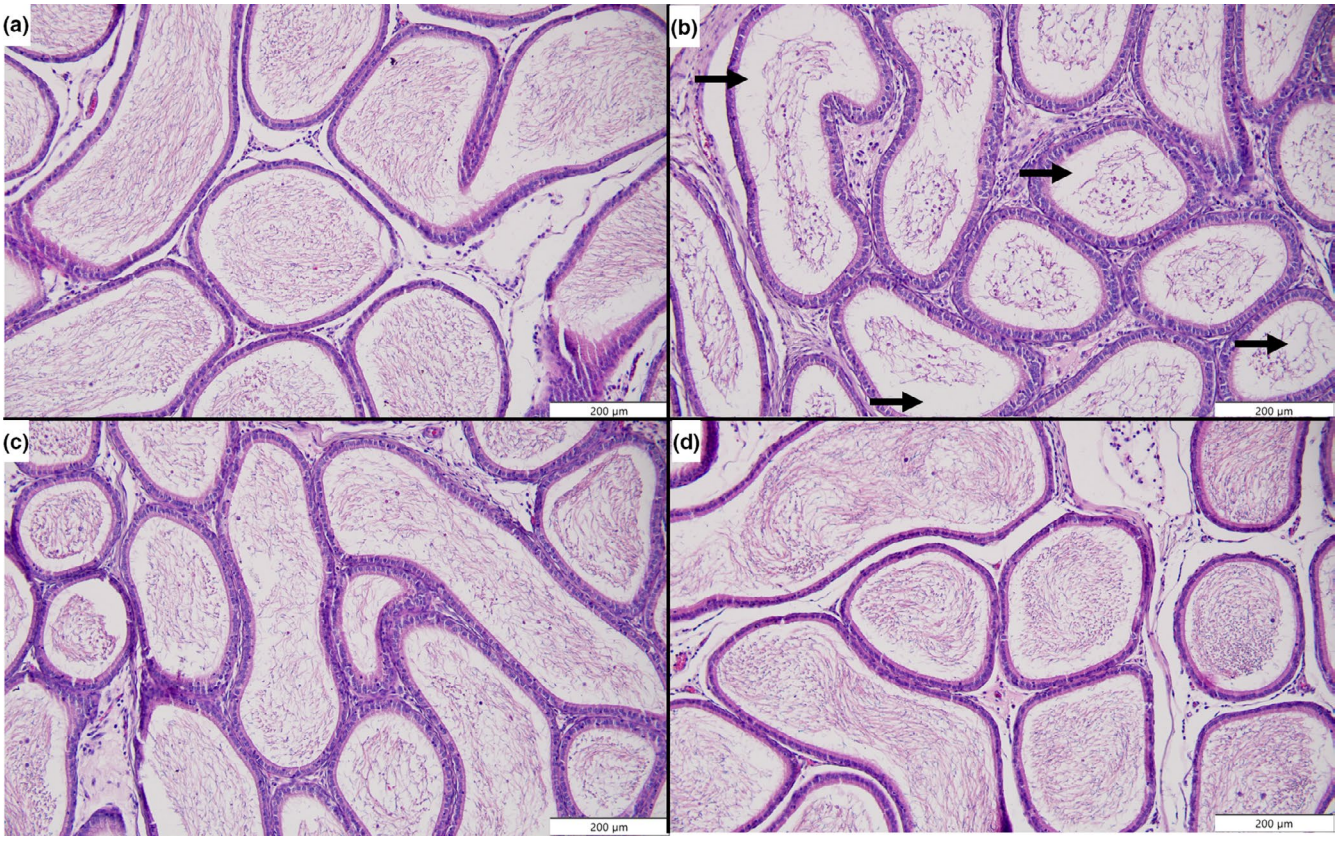

FIGURE 2 Light microscope images of epididymis stained by haematoxylin and eosin (H-E) staining. x200. Epididymis have normal histological architecture in control (a) and GA (d) groups. In the CP group (b), sperm count decreased in the ductus epididymis (arrow). GA improved decreased sperm count in the ductus epididymis caused by CP (c)

2.8 | Statistical analysis

Statistical analyses were accomplished by using SPSS 21.0 software. Differences between groups were evaluated by the one-way analysis of variance (ANOVA) followed by the Tukey post hoc test. $p \leq 0.05$ was accepted as statistically significant. All data were expressed as mean ± standard deviations.

3 | RESULTS

3.1 | Total number of testicular cells

As in Table 1, the total number of spermatogonia, Sertoli and Leydig cells was significantly decreased in rats of the CP group compared with the control group, but these parameters were significantly increased in the CP + GA group compared with the CP group ($p < 0.05$). GA group was observed to be similar to the control group.

3.2 | The total volume of testicular parameters

Compared with the control group, total testicular volume and total seminiferous tubule volume were significantly decreased in the CP group ($p < 0.05$), while no significant difference was observed in the total interstitial area volume. Compared with the CP group, a significant increase was observed in the total testicular volume and total seminiferous tubule volume in the CP + GA group ($p < 0.05$) However, no significant change was seen in the GA group compared with the control group. (Table 1).

3.3 | Height of germinal epithelium

The height of germinal epithelium significantly decreased in the CP group compared with the control group. Nevertheless, a significant increase was observed in the CP + GA group compared with the CP group ($p < 0.05$) But, the GA group was similar to the control group (Table 1).

3.4 | Histopathological evaluations

Testis and ductus epididymis were observed to have a normal histological structure in the control group (Figure 1a and Figure 2a). Compared with the control group, in the ductus epididymis, there are fewer sperm cells in the tubular lumen, and oedema in the area between the ducts was observed in the CP group (Figure 2b). In the

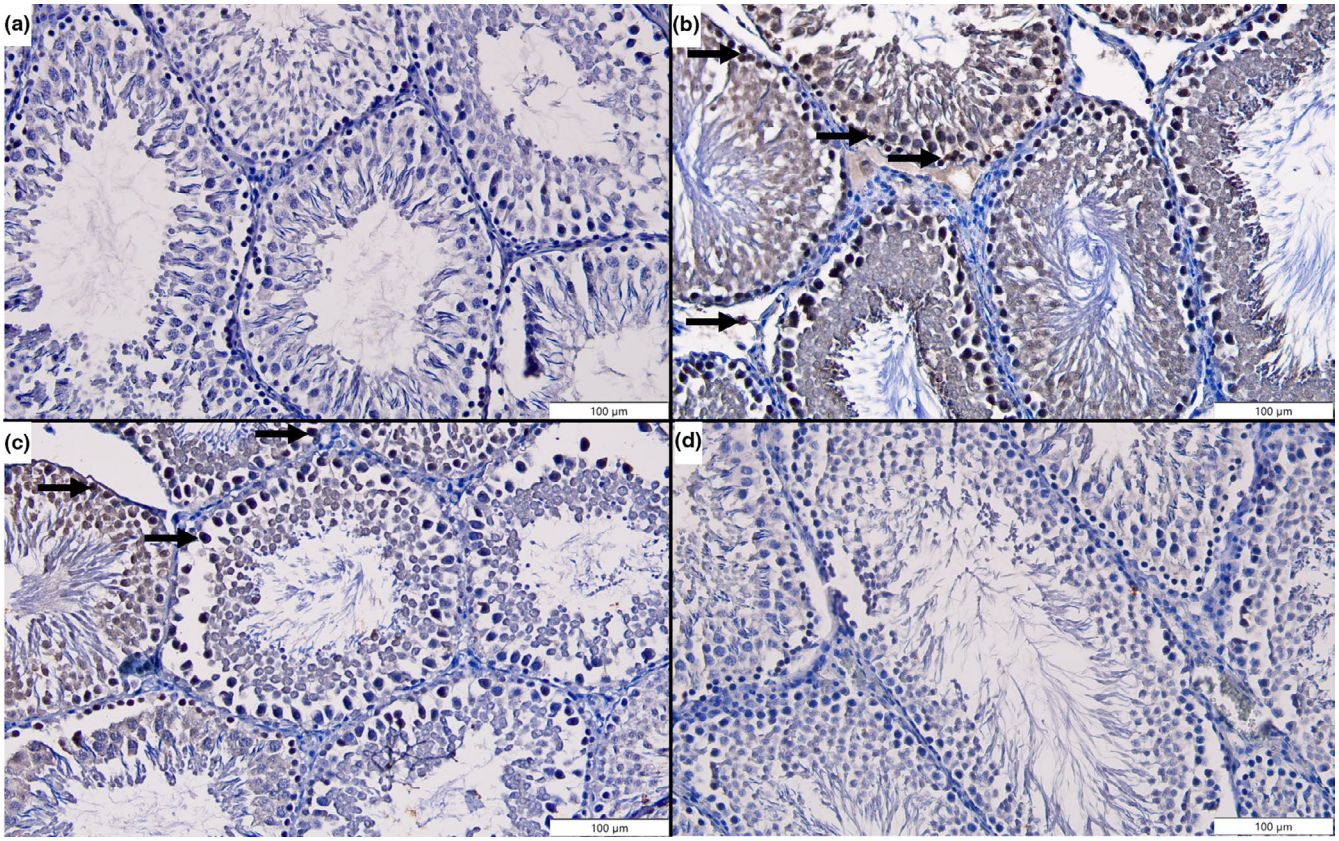

FIGURE 3 Light microscopic images of Caspase-3 expressions in the testis. x200. Arrows indicate immunopositive cells in groups. Control (a) and GA (d) groups are in normal histological architecture. CP triggered upregulation of Caspase-3 (b). GA caused downregulation of Caspase-3 (c)

testis tissues of the CP group, it was observed that atrophy in the seminiferous tubule, decreased sperm number in the tubule lumen, and a decrease in the number of tubular epithelial layers (Figure 1b). GA application improved these changes in both testis and epididymis (Figure 1c and Figure 2c). In addition, according to the Johnsen testicular biopsy score results, a lower testicular score was observed in the CP group compared with the control group. On the other hand, the testicular biopsy score of the CP + GA group was higher than the CP group (Figure 7b).

3.5 | Immunohistochemical evaluations of Caspase-3, Bax, Bcl-2 and 8-OHdG

As given in Table 2, just a few Caspase-3, Bax and 8-OHdG immunopositive cells were observed in the control and GA groups. A significant increase in the numerical density of Caspase-3 (Figure 3b), Bax (Figure 4b) and 8-OHdG (Figure 6b) immunopositive cells and a significant decrease in the numerical density of Bcl-2 (Figure 5b) immunopositive cells were observed in the CP group compared with the control group (Figures 3a, 4a, 5a, 6a). But, the numerical density of Caspase-3 (Figure 3c), Bax (Figure 4c) and 8-OHdG (Figure 6c) immunopositive cells significantly decreased in the CP +GA group, while the numerical density of Bcl-2 (Figure 5c) immunopositive cells significantly increased (p <.05) compared with the CP group (Table 2).

3.6 | Serum testosterone levels

Compared with the control group, testosterone level significantly decreased in animals of the CP group ($p < 0.05$). However, the testosterone level significantly increased in the CP + GA group compared with the CP group ($p < 0.05$). The testosterone level of animals in the GA group was similar to that of the control group (Figure 7a).

3.7 | Effects of GA on measurement of parameters related to oxidative stress in testis

When compared with the control group, it was observed that the MDA levels significantly increased (Figure 7c) and the activity of CAT, GSH and SOD enzymes activity significantly decreased (Figure 7d–f) in the CP group ($p < 0.05$). On the other hand, the MDA levels significantly decreased and the activity of CAT, GSH and SOD enzymes significantly increased in the GA + CP group compared with the CP group ($p < 0.05$).

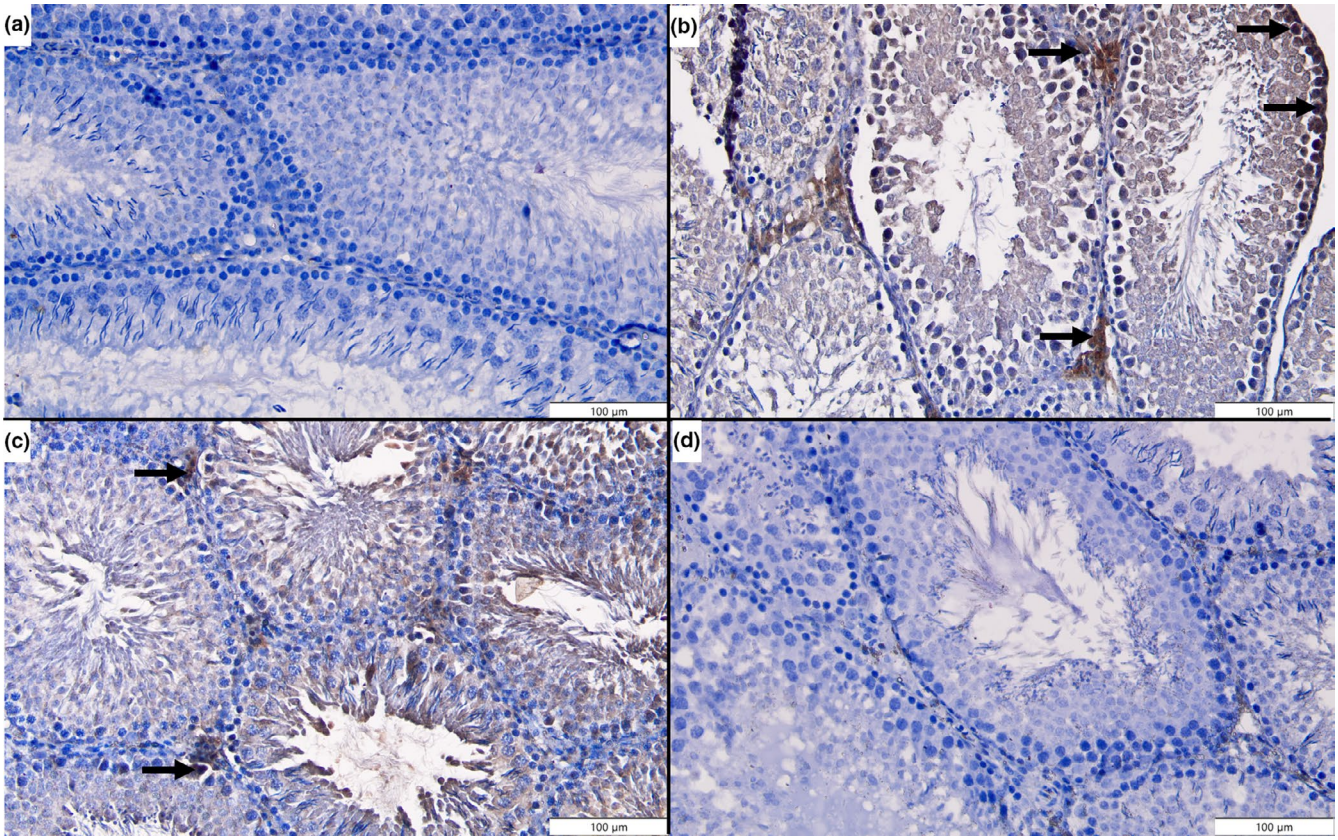

FIGURE 4 Light microscopic images of Bax expressions in the testis. x200. Arrows indicate immunopositive cells in groups. Control (a) and GA (d) groups are in normal histological architecture. CP triggered upregulation of Bax (b). GA decreased the upregulation of Bax triggered by Cp (c)

4 | DISCUSSION

The current study revealed that CP treatment caused a decrease in the total number of Sertoli, Leydig and spermatogonia cells and total testicular volume, as well as structural deterioration in the testis and epididymis. It also caused a significant increase in apoptosis, oxidative stress and DNA damage indexes and a decrease in testosterone secretion. However, GA significantly improved the side effects of CP by reducing testicular structural deformities, apoptosis, DNA damage, oxidative stress and improving testosterone secretion.

Chemotherapeutic agents are considered to be among the high-risk factors of infertility (Nna et al., 2020). Typically, infertility occurs after chemotherapy and radiotherapy. CP, an antineoplastic agent, is widely used to treat tumours. But, it causes cytotoxic effects in proliferating cells by damaging the binding of DNA base pairs. Excessive cell proliferation in spermatogenesis makes the testis more sensitive to these agents (Mercantepe et al., 2018). Therefore, protecting the testis from CP-induced toxicity has become an important issue in chemotherapy with CP (Afsar et al., 2017). Previous studies have reported that CP-induced testicular toxicity can be prohibited with the treatment of antioxidants such as melatonin, vitamin C and resveratrol (Almeer & Abdel Moneim, 2018; El-shafaei et al., 2018; Reddy et al., 2016). Additionally, it has been published that GA should protective effects against CP-induced nephrotoxicity, ototoxicity and genotoxicity of the bone marrow (Akomolafe et al. 2014; Shruthi et al., 2018; Kilic et al., 2019). However, in our literature review, no study was found on the effects of GA on testicular and epididymal damage induced by CP.

It has been reported that CP increases ROS production, lipid peroxidation and denaturation of structural proteins additionally decreases the activity of the antioxidant system and promotes cell apoptosis by activating p53 (Dasari & Tchounwou, 2014; Kohsaka et al., 2020). Oxidative stress is accepted as the result of the disruption of the balance between ROS production and antioxidant enzyme levels (Ekinci Akdemir et al., 2019). Decreased antioxidant enzymes cause the testis to remain vulnerable to the toxic effect of CP. Oxidative stress causes testicular damage, testicular apoptosis, DNA damage and male reproductive dysfunction, which can result in infertility (Shati, 2019). Previous studies have reported that CP treatment caused the increased in level of lipid peroxidation and the decreased in level of SOD, CAT and GSH (Azarbarz et al., 2020; Reddy et al., 2016). Similarly, Afsar et al., (2017) reported that CP increased the level of oxidative stress parameters, while decreased the activity of antioxidant enzymes. In line with previous studies (Afsar et al., 2017; Reddy et al., 2016), the current study proved that CP increased MDA levels and decreased activity of CAT, GSH and SOD enzymes in testicular tissue. The findings of our study indicated that GA can protect the testis against oxidative damage by repairing

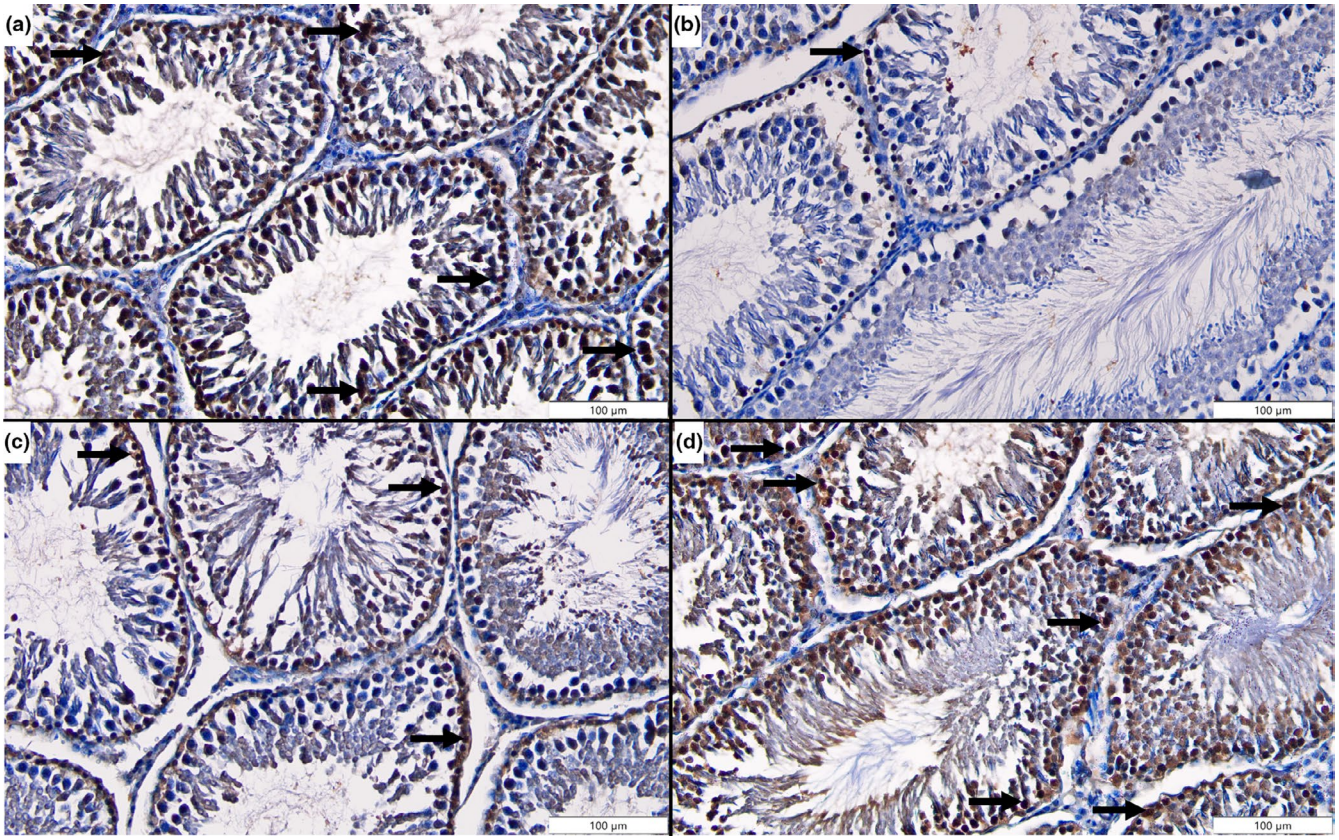

FIGURE 5 Light microscopic images of Bcl-2 expressions in the testis. x200. Arrows indicate immunopositive cells in groups. Intensive Bcl-2 immune positive cells were seen in the control and GA groups (a and d). Few Bcl-2 immune positive cells were seen in the CP group (b). In the CP+GA group, moderate Bcl-2 immune positive cells were seen (c)

the increased MDA levels and decreased activity of CAT, GSH and SOD enzymes in rats treated with CP. The beneficial effects of GA are mainly related to its antioxidant properties as it acts as a radical scavenger. Previous studies reported that in doxorubicin (DOX)-induced testicular injury, GA significantly improves restored MDA levels and decreased antioxidant enzymes (Olusoji et al., 2016). In addition, Oyagbemi et al., (2016) reported that GA significantly improved MDA levels, nitrite and H_2O_2 levels and decreased SOD, GSH in cyclophosphamide-induced testicular and epididymal damage.

According to their role in apoptosis, apoptotic proteins are classified as pro-apoptotic and anti-apoptotic proteins (Abotaleb et al., 2019). Bax protein, a pro-apoptotic protein, increases under oxidative stress conditions and subsequently releases the cytochrome C that impairs the mitochondrial membrane permeability (Fouad et al., 2017). Cytochrome C binds to apoptotic protease-activating factor 1 (Apaf-1) and activates it. Activated Apaf-1 forms the apoptosome. Apoptosis is maintained by caspases formed in response to cell death stimuli. The apoptotic protease-activating factor 1 (Apaf-1) controls caspase activation. As a result, activation of Caspase-3 that plays a key role in the execution of apoptosis is stimulated (Riedl et al., 2005). Caspase-3 is frequently used in studies to evaluate apoptosis, because the activation of Caspase-3 is an irreversible stage that induces apoptosis (Mercantepe et al., 2018; Nna et al., 2020). Proteins in the Bcl-2 families control cell death and survival by regulating the mitochondrial apoptotic pathway. Bcl-2, an anti-apoptotic protein, maintains mitochondrial membrane integrity (Fouad et al., 2017). Previous studies have reported that CP (a single dose of 6 mg/kg and 7 mg/kg) causes upregulation of Caspase-3 and downregulation of Bcl-2 (Kohsaka et al., 2020; Nna et al., 2020). Similarly, Aly and Eid (2020) have reported that CP treatment (a single dose of 7.5 mg/kg) increased the activity of Caspase-3 and Bax, while decreased the activity of Bcl-2 in testis. They also showed that resveratrol decreased the activity of Caspase-3 and Bax, but increased the activity of Bcl-2. In another study, Eren et al., (2020) reported that CP increased the caspase-3 immunoreactivity in the germinal epithelium and Leydig cells. However, they also revealed that amifostine and melatonin decreased the Caspase-3 immunoreactivity in the germinal epithelium and Leydig cells. The present study revealed that CP treatment significantly increased the expressions of Caspase-3 and Bax, which are important markers of the apoptotic index, while significantly decreased Bcl-2 expression in the testis. However, GA treatment significantly decreased the expression of Caspase-3 and Bax and increased the expression of Bcl-2. Thus, these findings of our study proved that GA could protect against CP-induced testicular toxicity by regulating the expression of Caspase-3, Bax and Bcl-2.

Morphometric examination of the testis is very important to determine male reproductive injury by CP-induced. Based on the

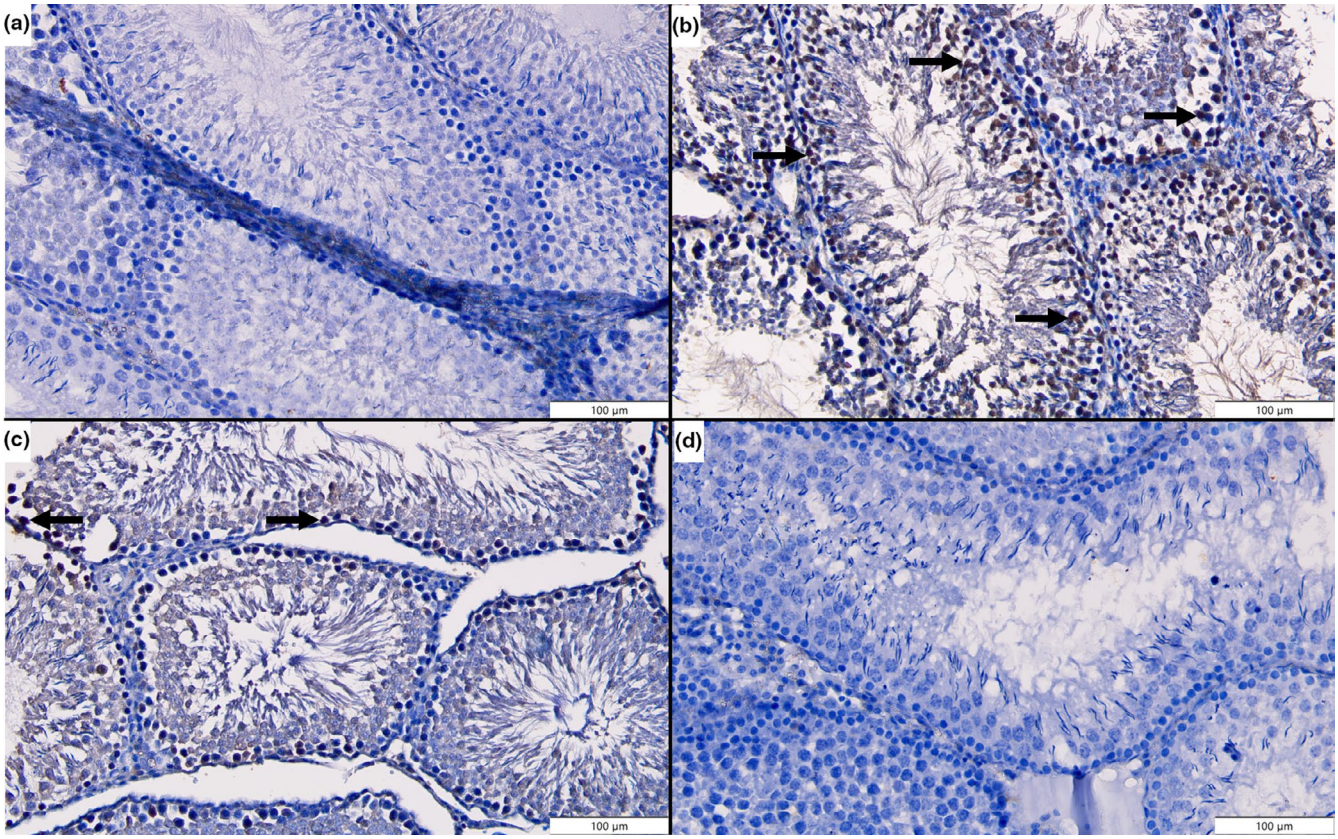

FIGURE 6 Light microscopic images of 8-OHdG expressions in the testis. x200. Arrows indicate immunopositive cells in groups. Control (a) and GA (d) groups are in normal histological architecture. CP triggered upregulation of 8-OHdG (b). GA decreased the upregulation of 8-OHdG triggered by Cp (c)

TABLE 2 Effect of GA on the numerical density of immunopositive cells (cell number/mm^3) in CP-induced rats

Groups	Caspase−3	Bax	Bcl−2	8-OHdG
Control	2,01 ± 0,82^b	1,86 ± 0,69^b	160,01 ± 13,58^b	3,43 ± 0,96^b
CP	112,29 ± 9,30^a	73,86 ± 7,47^a	38,71 ± 8,69^a	121,43 ± 8,94^a
CP + GA	32,71 ± 7,32^{a,b}	25,43 ± 6,78^{a,b}	80,43 ± 9,78^{a,b}	41,71 ± 6,68^{a,b}
GA	3,29 ± 0,76^b	1,71 ± 0,76^b	184,14 ± 11,01^b	4,29 ± 0,76^b

Note: Values are expressed as means ± *SD*. Significant differences as compared with the Control group at $^a p < 0.05$, Significant differences as compared with the CP group at $^b p < 0.05$

histological semi-quantitative evaluation, Jahan et al., (2018) reported that CP decreased sperm production, seminiferous tubule diameter, number of spermatogonia, spermatocytes and spermatids compared with the control group. They also showed that rutin co-treatment could ameliorate a decrease in sperm production, cell number and tubule diameter. Similarly, Azarbarz et al., (2020) revealed that CP treatment significantly decreased the diameter of the seminiferous tubules, germinal epithelium thickness, the number of spermatogonia, spermatocyte and Sertoli cells. In another study, semiquantitative data of Afsar et al., (2017) revealed that CP caused a reduction in the number of Leydig cells inducing the degradation in Leydig cells. They also showed that *Acacia hydaspica* extract ameliorated the degradation in Leydig cells. The quantitative findings of our study revealed that CP decreased the total number of spermatogonia, Sertoli and Leydig cells in the morphometric examination performed by unbiased stereological methods. This decrease in testicular cells may be a result of apoptosis induced by increased ROS production caused by CP (Köroğlu et al., 2019). Also, quantitative data of our study obtained using stereological methods demonstrated that total volume of the testis, the total volume of seminiferous tubule and germinal epithelial height significantly decreased in animals that received CP compared with control groups. We estimate that the decrease in these parameters of our study may have been due to the decrease in the total number of testicular cells caused by CP. These changes in testicular morphometric parameters confirmed that CP treatment causes testicular toxicity. However, GA treatment inhibited the total volume of the testis, the total volume of seminiferous tubule and germinal epithelial height.

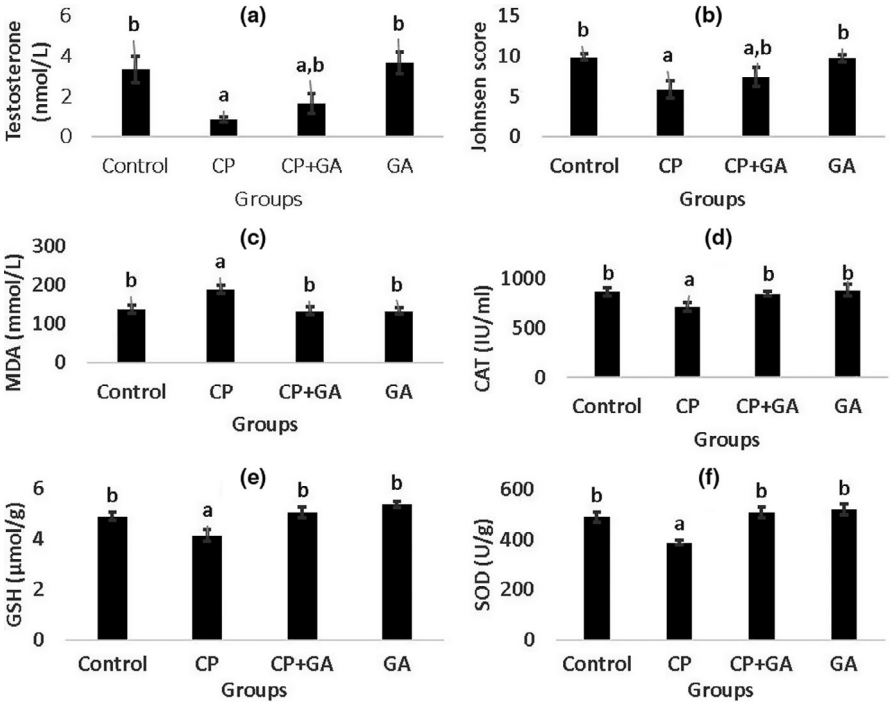

FIGURE 7 Effects of GA on testosterone (a), Johnsen score (b), MDA (c), CAT (d), GSH (e) and SOD (f) in CP-induced rats. Values are expressed as means ± SD. Significant differences as compared with the Control group at $^{a}P < 0.05$, Significant differences as compared with the CP group at $^{b}P < 0.05$

According to histopathological examinations of previous studies, Köroğlu et al., (2019) reported that CP caused the atrophy in seminiferous tubules, a decrease in spermatogenic cell lines and an increase in a number of abnormal spermatozoa. They also showed that Apocynin ameliorates these pathological changes caused by CP. Shati (2019) reported that CP increased abnormal sperm number, decreased sperm count and motility. Besides, they demonstrated that Resveratrol alleviated these structural deformities. Azarbarz et al., (2020) revealed that CP caused a significant decrease in Johnsen's testicular score. In accordance with these studies, The histopathological findings of our study proved that CP treatment caused the atrophy in the seminiferous tubules, a decreased sperm cells in tubular lumen, and a decrease in the number of germinal epithelial layers, and a significant decrease in the Johnsen testicular score. Additionally, CP caused the reduced mature sperm count in the epididymis. However, GA significantly restored these structural deteriorations caused by CP in testis. It is estimated that the decrease in sperm count in the epididymis may be related to the deterioration in spermatogenesis, as a consequence of the decrease in the number of spermatogenic cells caused by CP. In our study, the decreases in the total number of testicular cells, the germinal epithelium height, the Johnsen score and the increase in the number of Caspase-3 and Bax immunopositive cells confirm each other.

The previous studies reported that CP causes DNA damage by causing cross-linking of DNA double strands of proliferating cells especially in the testis (Mohammadnejad et al., 2012). 8-OHdG, an important biomarker of DNA damage and oxidative stress, is widely used in experimental studies to determine DNA damage (Köroğlu et al., 2019). Mitochondrial and nuclear DNA damage caused by ROS can be detected with 8-OHdG (Mercantepe et al., 2018).

Köroğlu et al., (2019) found that CP treatment induced a higher level of 8-OHdG compared with the control group in the testis of rats. But, they also showed that Apocynin alleviated the DNA damage reducing the levels of 8-OHdG. In another study, Eren et al., (2020) reported that the 8-OHdG was increased in the germinal epithelium and Leydig cells of CP-received rats. However, they also revealed that amifostine and melatonin decreased the levels of 8-OHdG in the germinal epithelium and Leydig cells. In our study, CP significantly increased 8-OHdG expression, which is a marker of DNA damage and oxidative injury. These findings of our study are consistent with previous studies (Amin et al. 2012; Mohammadnejad et al., 2012). However, GA treatment significantly reduced 8-OHdG expression in testis of CP-applied rats.

Testosterone that plays a prominent role in the initiation and maintenance of spermatogenesis is secreted by Leydig cells. Previous studies demonstrated that CP (a single dose of 7 mg/kg) decreased the testosterone levels but, rutin increased the testosterone levels compared with the CP group (Jahan et al., 2018). Similarly, Salem et al., (2012) reported that CP treatment (a single dose of 10 mg/kg) caused a decrease in the testosterone level and Selenium and Lycopene attenuated the decrease in testosterone levels induced by CP in the Wistar rat model. In addition, Salah Azab et al., (2019) found that CP treatment significantly decreased the testosterone levels but taurine significantly increased the testosterone levels in CP plus taurine group compared with the CP group. In our study, serum testosterone levels significantly decreased in rats which are applied CP. According to the findings of our study, it is estimated that the decrease in serum testosterone level caused by CP application may be related to the decrease in Leydig cell number as a result of increased apoptosis in Leydig cells. Because testosterone secretion is directly related to Leydig cell function and number (Gholami

Jourabi et al., 2021). Decreased testosterone levels caused by CP may disrupt the spermatogenesis process and thus may cause male infertility.

5 | CONCLUSION

Our findings demonstrated that CP may cause male reproductive damage through various mechanisms, such as oxidative stress, DNA damage, apoptosis, structural and functional defects. Furthermore, our findings revealed that GA may prevent CP-induced male reproductive toxicity by inhibiting oxidative stress, DNA damage, apoptosis and restoring the structural and functional defects in the testis and epididymis. According to the findings of this study, it is suggested that GA can be used as a protective agent against the side effects of CP treatment in testis and epididymis.

ACKNOWLEDGEMENTS

This study was carried out with the resources provided by the Department of Histology and Embryology, Faculty of Medicine and Vocational Higher School of Healthcare Studies, Van Yüzüncü Yıl University.

CONFLICT OF INTEREST

The authors declare that there are no conflicts of interest.

Data Availability Statement

The data of this study are available from the author upon reasonable request.

ORCID

Fikret Altındağ https://orcid.org/0000-0002-4074-5168

REFERENCES

Abarikwu, S. O., Simple, G., & Onuoha, C. S. (2020). Morphometric Evaluation of the Seminiferous Tubules and the Antioxidant Protective Effects of Gallic Acid and Quercetin in the Testis and Liver of Butyl Phthalate Treated Rats. *Indian Journal of Clinical Biochemistry*, *35*, 20–31. https://doi.org/10.1007/s12291-018-0788-0

Abotaleb, M., Samuel, S. M., Varghese, E., Varghese, S., Kubatka, P., Liskova, A., & Büsselberg, D. (2019). *Flavonoids in Cancer and Apoptosis*. *Cansers*, *11*, 28. https://doi.org/10.3390/cancers11010028

Afsar, T., Razak, S., khan, M. R., & Almajwal, A.. (2017). Acacia hydaspica ethyl acetate extract protects against cisplatin-induced DNA damage, oxidative stress and testicular injuries in adult male rats. *BMC Cancer*, *17*(1), https://doi.org/10.1186/s12885-017-3898-9

Ahmed, E. A., Omar, H. M., elghaffar, SKA, Ragb, SMM, & Nasser, A. Y.. (2011). The antioxidant activity of Vitamin C, DPPD and l-cysteine against Cisplatin-induced testicular oxidative damage in rats. *Food and Chemical Toxicology*, *49*(5), 1115–1121. https://doi.org/10.1016/j.fct.2011.02.002

Akomolafe, S. F., Akinyemi, A. J., & Anadozie, S. O. (2014). Phenolic Acids (Gallic and Tannic Acids) Modulate Antioxidant Status and Cisplatin Induced Nephrotoxicity in Rats. *International Scholarly Research Notices*, *2014*, 1–8. https://doi.org/10.1155/2014/984709

Almeer, R. S., & Abdel Moneim, A. E. (2018). Evaluation of the Protective Effect of Olive Leaf Extract on Cisplatin-Induced Testicular Damage in Rats. *Oxidative Medicine and Cellular Longevity*, *2018*, 1–11. https://doi.org/10.1155/2018/8487248

Altindağ, F., & Özdek, U. (2021). Protective Eff ects of Chitosan and Chitosan Oligosaccharide on Sodium Fluoride-Induced Testicular Damage in Male Rats: A Stereological and Histopathological Study. *Kafkas Univ Vet Fak Derg*, *27*(2), 183–189. https://doi.org/10.9775/kvfd.2020.25058

A.A. Aly, H, & G. Eid, B (2020). Cisplatin induced testicular damage through mitochondria mediated apoptosis, inflammation and oxidative stress in rats: Impact of resveratrol. *Endocrine Journal*, *67*(9), 969–980. https://doi.org/10.1507/endocrj.EJ20-0149

Amin, A., Abraham, C., Hamza, A. A., Abdalla, Z. A., Al-Shamsi, S. B., Harethi, S. A., & Daoud, S. (2012). A Standardized Extract ofGinkgobiloba Neutralizes Cisplatin-Mediated Reproductive Toxicity in Rats. *Journal of Biomedicine and Biotechnology*, *11*. https://doi.org/10.1155/2012/362049

Azarbarz, N., Shafiei Seifabadi, Z., Moaiedi, M. Z., & Mansouri, E. (2020). Assessment of the effect of sodium hydrogen sulfide (hydrogen sulfide donor) on cisplatin-induced testicular toxicity in rats. *Environmental Science and Pollution Research*, *27*(8), 8119–8128. https://doi.org/10.1007/s11356-019-07266-5

Beutler, E., Dubon, O., & Kelly, B. M. (1963). Improved method for the determination of blood glutathione. *Journal of Laboratory and Clinical Medicine*, *61*, 882–888.

Buege, J. A., & Aust, S. D. (1978). Microsomal lipid peroxidation. *Methods in Enzymology*, *52*, 302–310. https://doi.org/10.1016/S0076-6879(78)52032-6

Cahill, MM., Kett, M, McCAUSLAND, JE., Alcorn, D, & Bertram, JF. (1996). Glomerular stereology: Why, what and how to measure glomerular structure. *Nephrology*, *2*(5), 305–313. https://doi.org/10.1111/j.1440-1797.1996.tb00106.x

Ceylan, T., Kaymak, E., Cantürk, F., & Yakan, B. (2020). Research on the protective effect of caffeic acid phenethyl ester on testicular damage caused by cisplatin. *Turkish Journal of Medical Sciences*, *50*(8), 2032–2039. https://doi.org/10.3906/sag-2002-58

Dasari, S., & Bernard Tchounwou, P. (2014). Cisplatin in cancer therapy: Molecular mechanisms of action. *European Journal of Pharmacology*, *740*, 364–378. https://doi.org/10.1016/j.ejphar.2014.07.025

Dehghani, M A, Shakiba Maram, N, Moghimipour, E, Khorsandi, L, Atefi khah, M, & Mahdavinia, M (2020). Protective effect of gallic acid and gallic acid-loaded Eudragit-RS 100 nanoparticles on cisplatin-induced mitochondrial dysfunction and inflammation in rat kidney. *Biochimica et Biophysica Acta (BBA) - Molecular Basis of Disease*, *1866*(12), https://doi.org/10.1016/j.bbadis.2020.165911

Dubovskiy, IM, Martemyanov, VV, Vorontsova, YL, Rantala, MJ, Gryzanova, EV, & Glupov, VV (2008). Effect of bacterial infection on antioxidant activity and lipid peroxidation in the midgut of Galleria mellonella L. larvae (Lepidoptera, Pyralidae). *Comparative Biochemistry and Physiology Part C: Toxicology & Pharmacology*, *148*(1), 1–5. https://doi.org/10.1016/j.cbpc.2008.02.003

Ekinci Akdemir, F. N., Yildirim, S., Kandemir, F. M., Aksu, E. H., Guler, M. C., Kiziltunc Ozmen, H., Kucukler, S., & Eser, G. (2019). The antiapoptotic and antioxidant effects of eugenol against cisplatin-induced testicular damage in the experimental model. *Andrologia*, *51*(9), 1–8. https://doi.org/10.1111/and.13353

Elrashidy, R. A., & Hasan, R. A. (2020). Stromal cell-derived factor-1α predominantly mediates the ameliorative effect of linagliptin against cisplatin-induced testicular injury in adult male rats. *Cytokine*, *136*, https://doi.org/10.1016/j.cyto.2020.155260

El-shafaei, A., Abdelmaksoud, R., Elshorbagy, A., Zahran, N., & Elabd, R. (2018). Protective effect of melatonin versus montelukast in cisplatin-induced seminiferous tubule damage in rats. *Andrologia*, *50*(9), 1–8. https://doi.org/10.1111/and.13077

Eren, H., Mercantepe, T., Tumkaya, L., Mercantepe, F., Dil, E., Horsanali, M. O., & Yilmaz, A. (2020). Evaluation of the protective effects of amifostine and melatonin against cisplatin induced testis injury via oxidative stress and apoptosis in rats. *Experimental and Molecular Pathology*, *112*, https://doi.org/10.1016/j.yexmp.2019.104324

Fouad, A. A., Qutub, H. O., Fouad, A. E. A., Audeh, A. M., & Al-Melhim, W. N. (2017). Epigallocatechin-3-gallate counters cisplatin toxicity of rat testes. *Pharmaceutical Biology*, *55*(1), 1710–1714. https://doi.org/10.1080/13880209.2017.1322618

Gholami Jourabi, F., Yari, S., Amiri, P., Heidarianpour, A., & Hashemi, H. (2021). The ameliorative effects of methylene blue on testicular damage induced by cisplatin in rats. *Andrologia*, *53*(1), 1–10. https://doi.org/10.1111/and.13850

Gundersen, H. J. G. (1986). Stereology of arbitrary particles. *Journal of Microscopy*, *143*(1), 3–45. https://doi.org/10.1111/j.1365-2818.1986.tb02764.x

Jahan, S., Munawar, A., Razak, S., Anam, S., Ain, Q. U., Ullah, H., Afsar, T., Abulmeaty, M., & Almajwal, A. (2018). Ameliorative effects of rutin against cisplatin-induced reproductive toxicity in male rats. *BMC Urology*, *18*(1), https://doi.org/10.1186/s12894-018-0421-9

Johnsen, S. G. (1970). Testicular Biopsy Score Count – A Method for Registration of Spermatogenesis in Human Testes: Normal Values and Results in 335 Hypogonadal Males. *Hormone Research in Paediatrics*, *1*(1), 2–25. https://doi.org/10.1159/000178170

Kilic, K, Sakat, MS, Akdemir, FNE, Yildirim, S, Saglam, YS, & Askin, S (2019). Protective effect of gallic acid against cisplatin-induced ototoxicity in rats. *Brazilian Journal of Otorhinolaryngology*, *85*(3), 267–274. https://doi.org/10.1016/j.bjorl.2018.03.001

Kim, S. H., Jun, C. D., Suk, K., Choi, B. J., Lim, H., Park, S., Lee, S. H., Shin, H. Y., Kim, D. K., & Shin, T. Y. (2006). Gallic acid inhibits histamine release and pro-inflammatory cytokine production in mast cells. *Toxicological Sciences*, *91*(1), 123–131. https://doi.org/10.1093/toxsci/kfj063

Kohsaka, T., Minagawa, I., Morimoto, M., Yoshida, T., Sasanami, T., Yoneda, Y., Ikegaya, N., & Sasada, H. (2020). Efficacy of relaxin for cisplatin-induced testicular dysfunction and epididymal spermatotoxicity. *Basic and Clinical Andrology*, *30*(1), 3. https://doi.org/10.1186/s12610-020-0101-y

Köroğlu, K. M., Çevik, Ö., Şener, G., & Ercan, F. (2019). Apocynin alleviates cisplatin-induced testicular cytotoxicity by regulating oxidative stress and apoptosis in rats. *Andrologia*, *51*(4), e13227. https://doi.org/10.1111/and.13227

Lartillot, S., Kedziora, P., & Athias, A. (1988). Purification And Characterization Of A New Fungal Catalase. *Preparative Biochemistry*, *18*(3), 241–246. https://doi.org/10.1080/00327488808062526

Mayhew, T. M., & Gundersen, H. J. (1996). "If you assume, you can make an ass out of u and me": A decade of the disector for stereological counting of particles in 3D space. *Journal of Anatomy*, *188*, 1–15

Mercantepe, F., Mercantepe, T., Topcu, A., Yılmaz, A., & Tumkaya, L. (2018). Protective effects of amifostine, curcumin, and melatonin against cisplatin-induced acute kidney injury. *Naunyn-Schmiedeberg's Archives of Pharmacology*, *391*(9), 915–931. https://doi.org/10.1007/s00210-018-1514-4

Mohammadnejad, D., Abedelahi, A., Soleimani-rad, J., Mohammadi-roshandeh, A., Rashtbar, M., & Azami, A. (2012). Degenerative effect of cisplatin on testicular germinal epithelium. *Advanced Pharmaceutical Bulletin*, *2*(2), 173–177. https://doi.org/10.5681/apb.2012.026

Nna, V. U., Ujah, G. A., Suleiman, J. B., Mohamed, M., Nwokocha, C., Akpan, T. J., Ekuma, H. C., Fubara, V. V., Kekung-Asu, C. B., & Osim, E. E. (2020). Tert-butylhydroquinone preserve testicular steroidogenesis and spermatogenesis in cisplatin-intoxicated rats by targeting oxidative stress, inflammation and apoptosis. *Toxicology*, *441*, https://doi.org/10.1016/j.tox.2020.152528

Noorafshan, A. (2014). Stereology as a valuable tool in the toolbox of testicular research. *Annals of Anatomy - Anatomischer Anzeiger*, *196*(1), 57–66. https://doi.org/10.1016/j.aanat.2012.07.008

Olusoji, M. J., Oyeyemi, O. M., Asenuga, E. R., Omobowale, T. O., Ajayi, O. L., & Oyagbemi, A. A. (2016). Protective effect of Gallic acid on doxorubicin-induced testicular and epididymal toxicity. *Andrologia*, *49*(4), e12635. https://doi.org/10.1111/and.12635

Owumi, S. E., Nwozo, S. O., Effiong, M. E., & Najophe, E. S. (2020). Gallic acid and omega-3 fatty acids decrease inflammatory and oxidative stress in manganese-treated rats. *Experimental Biology and Medicine*, *245*(9), 835–844. https://doi.org/10.1177/1535370220917643

Oyagbemi, A. A., Omobowale, T. O., Saba, A. B., Adedara, I. A., Olowu, E. R., Akinrinde, A. S., & Dada, R. O. (2016). Gallic acid protects against cyclophosphamide-induced toxicity in testis and epididymis of rats. *Andrologia*, *48*(4), 393–401. https://doi.org/10.1111/and.12459

Reddy, K. P., Madhu, P., & Reddy, P. S. (2016). Protective effects of resveratrol against cisplatin-induced testicular and epididymal toxicity in rats. *Food and Chemical Toxicology*, *91*, 65–72. https://doi.org/10.1016/j.fct.2016.02.017

Riedl, S. J., Li, W., Chao, Y., Schwarzenbacher, R., & Shi, Y. (2005). Structure of the apoptotic protease-activating factor 1 bound to ADP. *Nature Com*, *13*, 926–933. https://www.nature.com/articles/nature0346 https://doi.org/10.1038/nature0346510.1038/nature03465

Azab, SS, kamel, I, Ismail, NN, El Din Hosni, H, & El Fatah, MA (2019). The defensive role of taurine against gonadotoxicity and testicular apoptosis effects induced by cisplatin in rats. *Journal of Infection and Chemotherapy*, *26*, 51–57. https://doi.org/10.1016/j.jiac.2019.07.004

Salem, E. A., Salem, N. A., Maarouf, A. M., Serefoglu, E. C., & Hellstrom, W. J. G. (2012). Selenium and lycopene attenuate cisplatin-induced testicular toxicity associated with oxidative stress in Wistar rats. *Urology*, *79*(5), 1184.e1–1184.e6. https://doi.org/10.1016/j.urology.2011.12.006

Shati, A. A. (2019). Resveratrol improves sperm parameter and testicular apoptosis in cisplatin-treated rats: Effects on ERK1/2, JNK, and Akt pathways. *Systems Biology in Reproductive Medicine*, *65*(3), 236–249. https://doi.org/10.1080/19396368.2018.1541114

Shruthi, S., & Bhasker Shenoy, K. (2018). Genoprotective effects of gallic acid against cisplatin induced genotoxicity in bone marrow cells of mice. *Toxicology Research*, *7*(5), 951–958

Sun, Y., Oberley, L. W., & Li, Y. (1988). A simple method for clinical assay of superoxide dismutase. *Clinical Chemistry*, *34*, 497–500 https://doi.org/10.1093/clinchem/34.3.497

Tomar, A., Vasisth, S., Khan, S. I., Malik, S., Nag, T. C., Arya, D. S., & Bhatia, J. (2017). Galangin ameliorates cisplatin induced nephrotoxicity in vivo by modulation of oxidative stress, apoptosis and inflammation through interplay of MAPK signaling cascade. *Phytomedicine*, *34*, 154–161. https://doi.org/10.1016/j.phymed.2017.05.00

Whirledge, S. D., Garcia, J. M., Smith, R. G., & Lamb, D. J. (2015). Ghrelin partially protects against cisplatin-induced male murine gonadal toxicity in a GHSR-1a-dependent manner. *Biology of Reproduction*, *92*, 1–11

Zhu, L., Gu, P. Q., & Shen, H. (2019). Gallic acid improved inflammation via NF-κB pathway in TNBS-induced ulcerative colitis. *International Immunopharmacology*, *67*, 129–137. https://doi.org/10.1016/j.intimp.2018.11.049

How to cite this article: Altındağ, F., & Meydan, İ. (2021). Evaluation of protective effects of gallic acid on cisplatin-induced testicular and epididymal damage. *Andrologia*, 00, e14189. https://doi.org/10.1111/and.14189